

# Prediction of pregnancy stage by ultrasonography in the Sarda sheep: a preliminary study



GIULIA FENU<sup>1</sup>, GIUSEPPE ARGIOLOS<sup>1</sup>, MICHELE PAZZOLA<sup>2,\*</sup>

<sup>1</sup> Sementusa Association, 09040 Senorbi (SU) via Torino 13/b, Italy

<sup>2</sup> Department of Veterinary Medicine, University of Sassari, via Vienna 2, 07100 Sassari, Italy

## SUMMARY

Measures of foetal growth during gestation have been published for several goat and sheep breeds to calculate the estimated gestational stage. Up to date, no study is available in the literature for the Sarda sheep. The aim of this study was to investigate, by ultrasonography, the foetal and placental morphometry in the Sarda sheep. A total of 256 ultrasonographic images were achieved from six ewes from day 24 of pregnancy (D24) to D92. The crown to rump length in cm (CRL) was recorded and, using visual scales score, foetal ossification (1 = absence; 2 = a few; 3 = several ossifications) and development of placental cotyledons (1 = absence; 2 = visible but immature; 3 = mature) were categorised. The data regarding CRL were analysed using a MIXED procedure while aspects of ossification and cotyledons using the Fisher's exact test. The effect of the pregnancy stage on CRL was statistically significant ( $p < 0.001$ ) and all the stages were differentiable each other. The least squares means of CRL spanned from 1.33 (D24 to D30) to 9.85 cm (D55 to D60). The effects of parity and lambing rate on CRL were not significant and the total variance attributable to the random effect of the single sheep was negligible. Based on the aspect of both ossification and cotyledons, it was possible to differentiate pregnancy stages between D31 to D50. These results are useful for veterinarians, in the field of reproductive management of Sarda sheep farms, to provide a consistent prediction of the date of lambing.

## KEY WORDS

Ewe, foetus, echography, lambing.

## INTRODUCTION

The ultrasound technique has been used for decades in veterinary medicine, particularly in the management of clinical disorders and reproductive systems of companion <sup>1</sup> and livestock species <sup>2,3,4</sup>. Overall, ultrasonography is a safe process both for the examined animal and the veterinarian and nowadays, because of the marketing of modern and transportable equipment, it can be easily performed on the field <sup>5</sup>.

Ultrasonographic examination to manage reproduction and pregnancy diagnosis in small ruminants farming is well recognized <sup>6</sup>. In meat sheep farming and productions, ultrasound diagnosis has improved the flock management, and the procedure is also performed to predict sheep carcass performances <sup>5,7</sup>. Nevertheless, the method is now an essential part of health planning and farm productivity, mainly for reproductive improvement and pregnancy diagnosis as highlighted by Scott <sup>5</sup> and Meinecke-Tillmann <sup>8</sup>. Also, field veterinarians in the sector of dairy sheep farming are often asked to predict breeding and reproductive potential of rams <sup>9,10</sup>, pregnancy stage and lambing date of sheep when oestrus and breeding dates are unknown. This allows to cull unproductive animals, get an early lambing, a longer season of milk production and finally a better farm management <sup>11-13</sup>. Moreover, information about

pregnancy and stage of pregnancy allow to optimize pharmacological treatments, avoiding teratogenic molecules, and the efficacy of vaccine prophylaxis <sup>11-13</sup>.

In the sector of dairy sheep, the countries of Southern Europe are the leading in terms of heads, productions and economic profit <sup>14</sup>. Sardinia is an insular region of Italy in the middle of the Mediterranean Sea where about 3 million dairy sheep are reared using the semi-extensive methods <sup>15</sup> and the local breed, the Sarda. The Sarda is the most common dairy sheep breed in Italy with 180,000 animals and 700 herds officially recorded in the flock book <sup>16</sup> and it is also appreciated in North African and East European countries <sup>15</sup>. Measures of foetal growth during gestation have been published for small ruminant species, from several goat and sheep breeds to calculate, via predictive equations, the estimated gestational stage <sup>3</sup>. Up to date, no study is available in the literature relating to a precise morphometric assessment of the foetal staging in the Sarda sheep.

The aim of this preliminary study is to investigate, by means of ultrasonography and the resultant on-field traits, the embryonal and foetal (foetal from this point), and placental morphometry in the Sarda sheep and provide a suitable tool to predict pregnancy stages.

## MATERIALS AND METHODS

Specific authorization was released for the procedures of the present study from the Animal Ethics and Welfare Committee

Corresponding Author:  
Michele Pazzola (pazzola@uniss.it)

at the University of Sassari, Italy (Organismo Preposto alla Benessere e alla Sperimentazione Animale, OPBSA) with the protocol number 0004372/2021. Sheep used for the present study belonged to a private commercial farm located in south-west Sardinia, with a flock of about 600 sheep of Sarda breed. The farmer joined the study on a voluntary basis.

At the farm, oestrus synchronization and ultrasonographic examination of ewes were performed under the control of the veterinarian (the first author of the present study, G.F.) and were part of the routine procedures to improve reproduction and production traits. In detail, the flock was submitted to oestrus synchronization using the following scheme, as recommended by the manufacturers and the common methods for oestrus synchronization in sheep<sup>17</sup>:

- i) 14 days before rams were allowed to join the flock: insertion of a 20 mg fluorogestone acetate intravaginal sponge per each ewe (Crono-Gest spugne 20 mg, MSD Animal Health S.r.l., Segrate, Italia);
- ii) 12 days after sponges' insertion, i.e. two days before rams were allowed to join the flock: removal of intravaginal sponges and intramuscular injection of 350 IU/ewe PMSG (Folligon MSD Animal Health S.r.l.; Segrate, Italia);
- iii) day 0 (D0): the day rams were allowed to join the flock (1 ram/25 ewes). The D0 has been accounted as the day of fecundation.

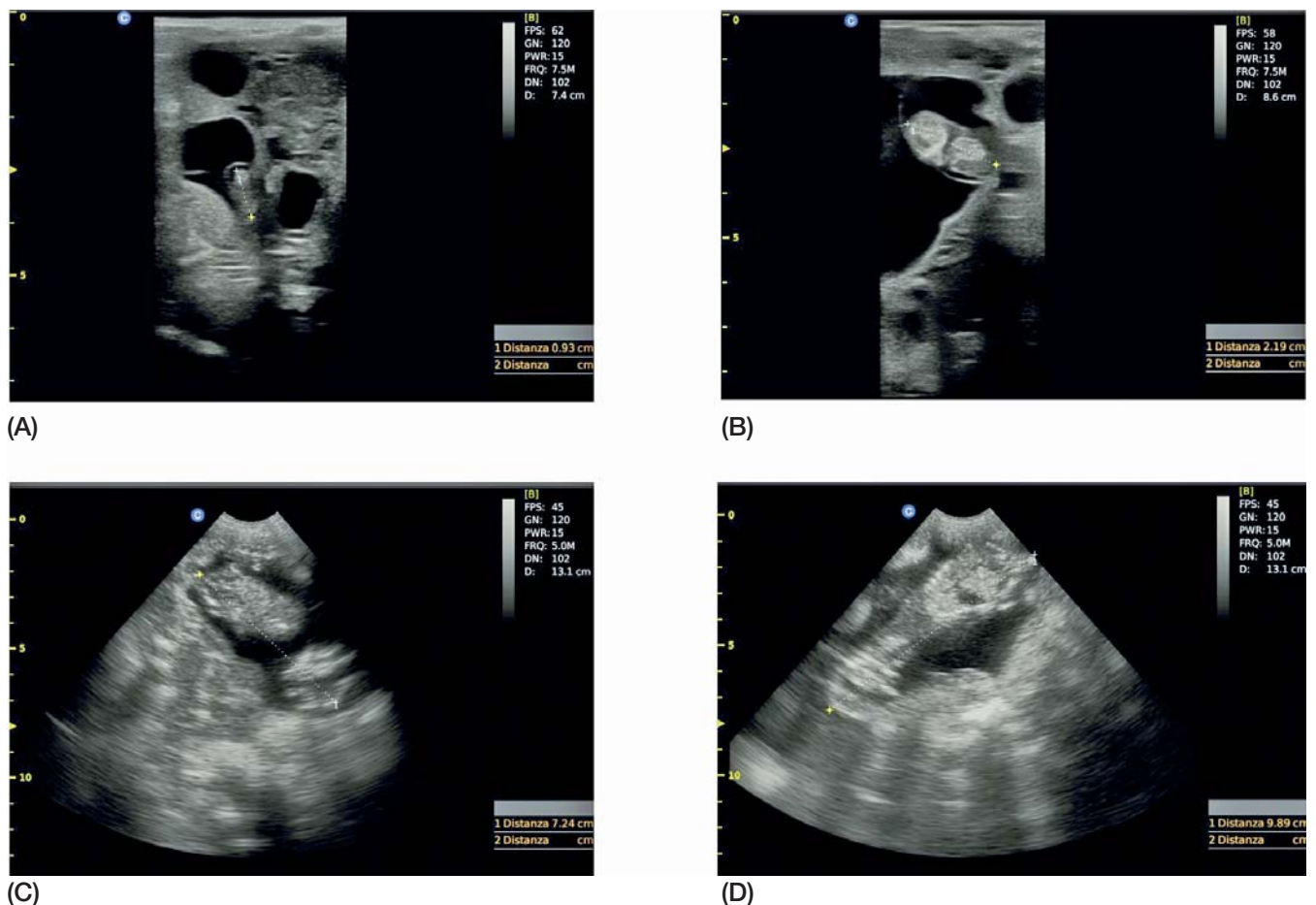
Six pregnant ewes of Sarda breed were randomly chosen from the flock and used for the present study: five were of second pregnancy with an average age of 1.7 years; and one was of third

pregnancy and 2.9 years old. Ewes were weighed using a static scale (model D440; manufacturer Società Cooperativa Bilanciai, Modena, Italy). Ultrasonographic images were achieved using an ultrasound scanner (Eco3Vet Expert PW Doppler, Multimage s.r.l., Cavaria Varese, Italy). Images were collected during the pregnancy from day 24 after rams were allowed to join the flock (D24) until the day foetuses were too large to be visualized within a single image enclosed in the scanner's screen. During the first stage of pregnancy, about up to D40, the scanner was equipped with a 7.5 MHz linear probe and the transrectal examination was used. Later, from D40 to the end of the trial, transabdominal examinations were performed using a 5.0 MHz micro-convex probe.

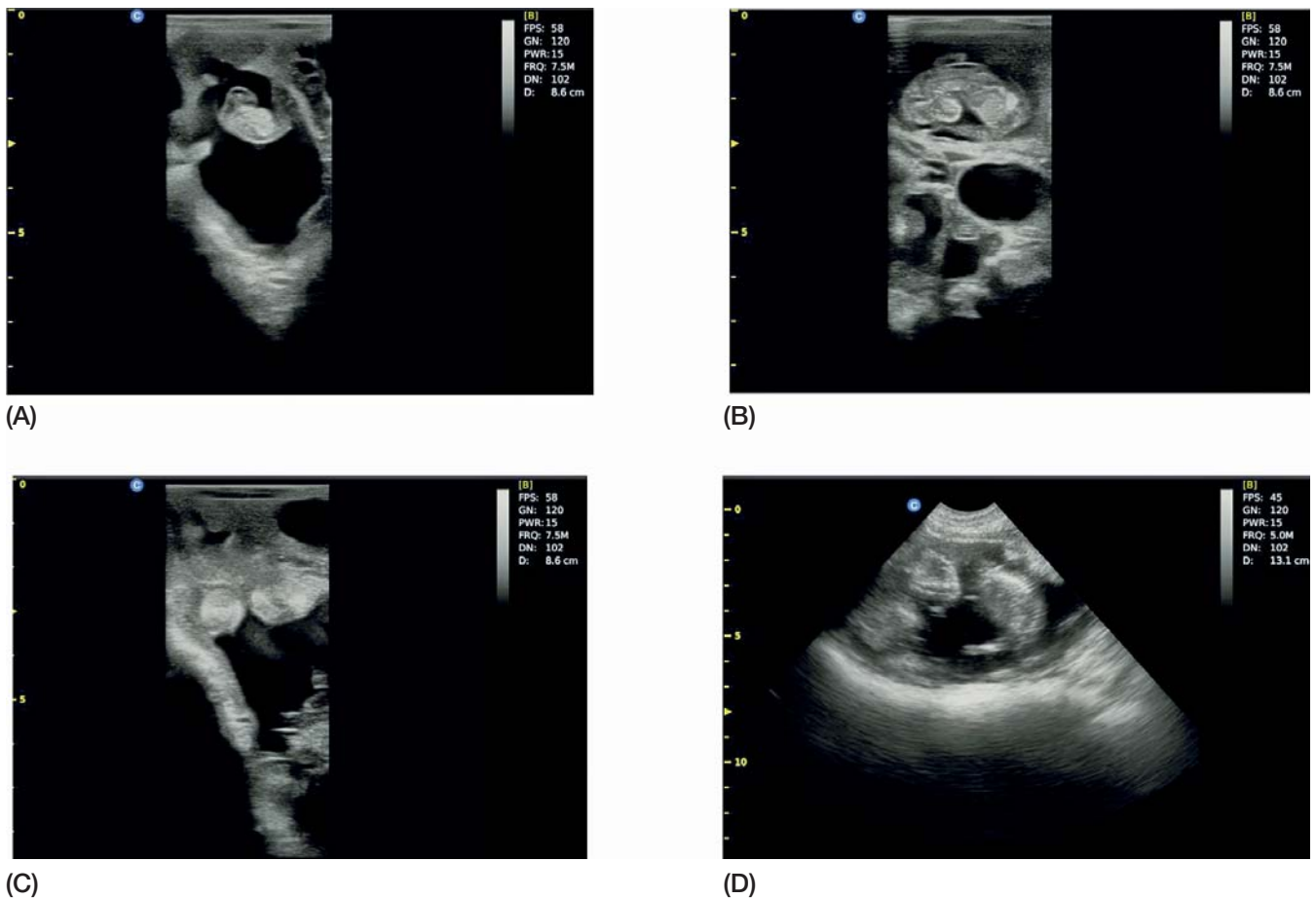Ultrasound examinations were performed with ewes standing in the milking parlour, and it took about one minute per each ewe to achieve a useful ultrasound image. A layer of ultrasound gel was always used both for transrectal and transabdominal examinations to prevent mucosal or skin irritations.

Ultrasound examinations were performed during the sampling sessions with the following sequence: daily from D24 to D58 (35 sampling sessions); on D63; on D70; on D77; on D84; on D92. Images were saved as electronic files during sampling session and later examined to achieve the following traits:

- the length of foetuses in cm, namely the crown to rump length, CRL, measured from the rostral point of the cranium to the caudal point of trunk<sup>3</sup>;
- foetal ossification as a measure of fetal development<sup>3,18</sup> using a visual scale score (1 = absence; 2 = a few, i.e. two or less;



**Figure 1** - Ultrasound images of Sarda sheep foetuses with measurement of crown-rump length according to pregnancy stage: (A), on day 24 of pregnancy (D24); (B), D34; (C), D52; (D), D58.



**Figure 2** - Ultrasound images of Sarda sheep fetuses with different scores of foetal ossification and development of placental cotyledons according to pregnancy stage: (A), absence of both ossification and cotyledons on day 28 of pregnancy (D28); (B), a few ossifications and immature cotyledons on D37; (C): immature cotyledons on D42; (D), several ossifications and mature cotyledons on D47. Scale score of ossification: 1 = absence; 2 = a few, i.e. two or less; 3 = several ossifications, i.e. three or more ossifications; scale score of placental cotyledons: 1 = absence; 2 = visible but immature; 3 = mature, i.e. placental cotyledons which are more echogenic and brighter than immature ones and appear as 'C-shaped'.

3 = several ossifications, i.e. three or more ossifications); - and development of placental cotyledons as a measure of pregnancy stage using a visual scale score (1 = absence; 2 = visible but immature; 3 = mature, i.e. placental cotyledons which are more echogenic and brighter than immature ones and appear as 'C-shaped'<sup>9,19</sup>).

In order to have a practical and rapid tool to measure embryofetal length on the field, the CRL was computed considering the shortest distance, without using a caliper and without considering the curvature of the dorsal spine (Figure 1). Similarly, foetal ossification and development of placental cotyledons were assessed using a practical evaluation, i.e. the visual scale scores as represented in Figure 2.

In the case of ewes with multiple pregnancy, CRL, foetal ossification and placental cotyledons were achieved from the first foetus observed by the ultrasound probe, which was assumed to be representative of the twins or triplets.

Finally, lambing dates were recorded, and lambs weighed using a static scale (model D440; manufacturer Società Cooperativa Bilanciai) at the age of 15 days.

The achieved traits were grouped into classes (stages) of 5 or more sampling days: stage 1, from 24 to 30 days of pregnancy (D24 to D30); stage 2 (D31 to D35); stage 3 (D36 to D40); stage 4 (D41 to D45); stage 5 (D46 to D50); stage 6 (D51 to

D55); stage 7 (D56 to D60); stage 8 (D61 or more, i.e. to D92). The data of 207 observations regarding CRL between D24 and D60 were analysed using a MIXED procedure and the following model:

$$Y_{ijkl} = \mu + PS_h + Parity_i + LR_j + Ewe_k + e_{ijkl}$$

where  $Y_{ijkl}$  is the CRL;  $\mu$  is the overall intercept of the model;  $PS_h$  is the fixed effect of the  $h^{th}$  classes of pregnancy stage above reported (7 classes; class 1: D24 to D30; class 2: D31 to D35; class 3: D36 to D40; class 4: D41 to D45; class 5: D46 to D50; class 6: D51 to D55; class 7: D56 to D60);  $Parity_i$  is the effect of the  $i^{th}$  order of ewes' pregnancy computed as covariate (two classes; second and third pregnancy);  $LR_j$  is the effect of the  $j^{th}$  lambing rate computed as covariate (three classes; single, twin and triplet);  $Ewe_k$  is the random effect of the  $k^{th}$  ewe (6 different ewes);  $e_{ijkl}$  is the error. Differences among least square means (LSmeans) of the classes were estimated by the Bonferroni test.

Data regarding foetal ossification and development of placental cotyledons between D24 and D92 were likewise grouped into the above reported classes of pregnancy stage and analysed using the Fisher's exact test.

Statistical analyses were performed using the SAS software (version 9.4, SAS Institute Inc., Cary, NC) and the effects declared significant at  $p < 0.05$ .

**Table 1** - Descriptive statistics of crown-rump length (CRL, n = 216) of fetuses from six Sarda sheep according to the pregnancy stage from day 24 (D24) to day 77 (D77).

Pregnancy stage	CRL (cm)					
	n	mean	SD	95% CI	min	max
D24 to D30	36	1.38	0.32	1.20 - 1.57	0.70	1.85
D31 to D35	30	2.29	0.31	2.09 - 2.49	1.76	2.80
D36 to D40	30	3.11	0.31	2.91 - 3.32	2.57	3.72
D41 to D45	30	4.61	0.60	4.41 - 4.81	3.60	5.65
D46 to D50	30	6.33	0.51	6.12 - 6.53	5.69	7.68
D51 to D55	30	8.04	0.75	7.84 - 8.24	7.00	9.49
D56 to D60	21	9.93	0.66	9.68 - 10.17	9.00	11.4
D61 to D77	9	12.98	1.31	12.61 - 13.35	11.50	15.09

SD: standard deviation; 95% CI: 95% confidence interval; min e max: minimum and maximum values.

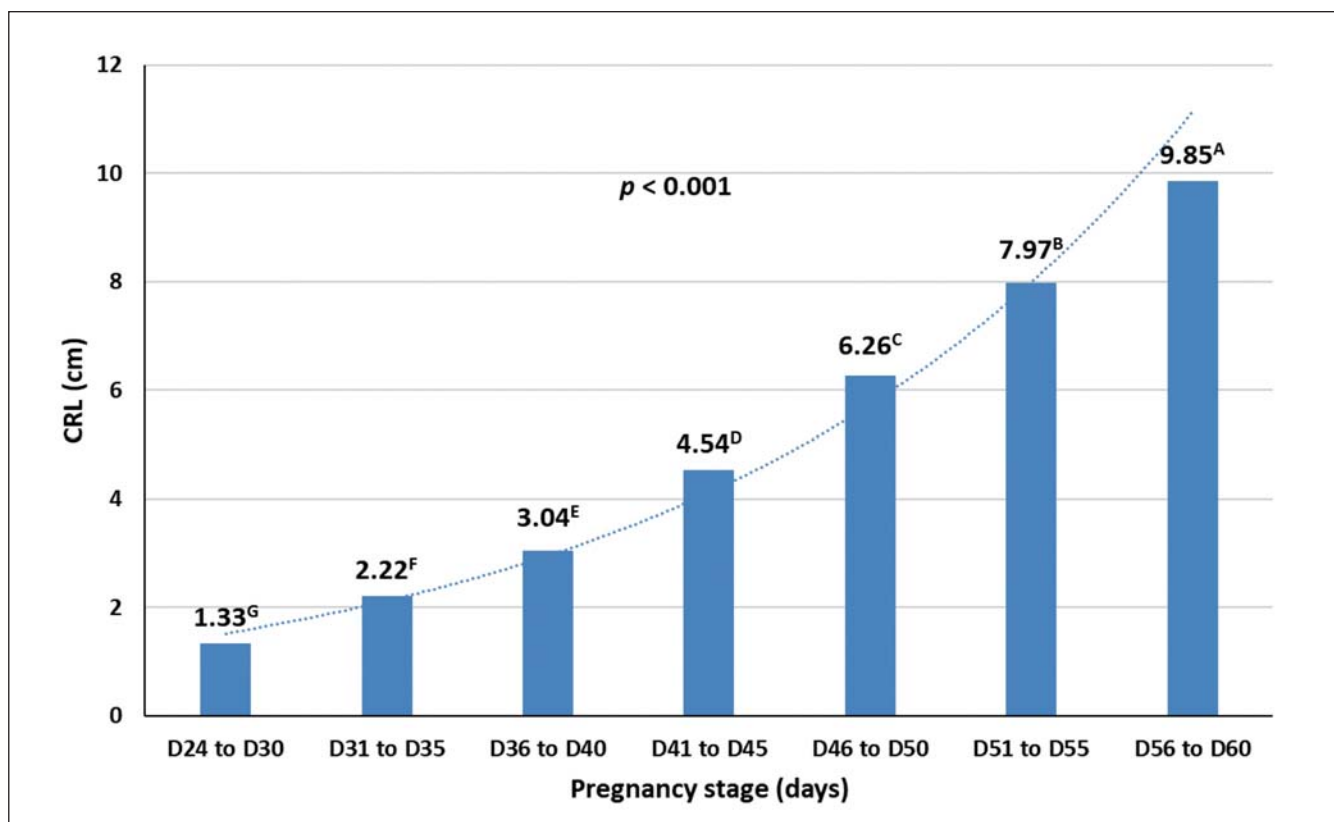
## RESULTS

Mean live weight of ewes was 48.2 kg (range: 45.5 - 50 kg), in line with the characteristics reported in the flock book<sup>16</sup>. The mean duration of pregnancy, calculated on the basis of D0 (the day rams joined the synchronized ewes), was 146.8 days with minimum and maximum durations of 145 and 151 days, respectively. No abortion was recorded, and all the fetuses detected by ultrasonography were born. The weights of lambs at the age of 15 days were between the minimum and maximum values of 5.2 and 7.2 kg, average 6.2 kg.

Table 1 summarizes the descriptive statistics of the 216 CRL records of the fetuses recorded by ultrasonography from D24 to D77 of pregnancy.

As regard the number of records for the different classes of pregnancy order, 172 records were achieved from 5 ewes of second pregnancy, and 35 records from 1 ewe of third pregnancy; as regard the lambing rate, 102 records from 3 ewes with single lamb, 72 records from 2 ewes with twin lambs and 33 records from 1 ewe with triplets.

Ultrasound images with measurement of CRL throughout the stages of pregnancy are reported in Figure 1.



**Figure 3** - Graphic representation of crown-rump length (CRL, n = 207) of fetuses from six Sarda sheep according to the pregnancy stage from day 24 (D24) to day 60 (D60), with least squares means compared by the Bonferroni test.

<sup>A-G</sup> least squares means with different superscript are different at  $p < 0.001$ .

**Table 2** - Aspect of foetal ossification and placental cotyledons using visual scale scores from fetuses of six Sarda sheep, according to the pregnancy stage from day 24 (D24) to day 92 (D92), with respective comparisons between stages and results of Fisher's exact test (n = 256).

Pregnancy stage	n	Ossification			Comparison and Fisher's exact test	Cotyledons			Comparison and Fisher's exact test
		absence	few	several		absence	immature	mature	
D24 to D30	42	42	0	0	-	42	0	0	-
D31 to D35	30	30	0	0	D24-30 vs. D31-35 NS	30	0	0	D24-30 vs. D31-35 NS
D36 to D40	30	6	24	0	D31-35 vs. D36-40 ***	13	17	0	D31-35 vs D36-40 ***
D41 to D45	30	0	24	6	D36-40 vs. D41-45 ***	0	20	10	D36-40 vs D41-45 ***
D46 to D50	30	0	0	30	D41-45 vs. D46-50 ***	0	0	30	D41-45 vs D46-50 ***
D51 to D55	30	0	0	30	D46-50 vs. D51-55 NS	0	0	30	D46-50 vs D51-55 NS
D56 to D60	30	0	0	30	D51-55 vs. D56-60 NS	0	0	30	D51-55 vs D56-60 NS
D61 to D92	30	0	0	30	D56-60 vs. D61-92 NS	0	0	30	D56-60 vs D61-92 NS

Significance level: NS = non significant; \*\*\* =  $p < 0.001$ .

Scale score of ossification: 1 = absence; 2 = a few, i.e. two or less; 3 = several ossifications, i.e. three or more ossifications); scale score of placental cotyledons: 1 = absence; 2 = visible but immature; 3 = mature, i.e. placental cotyledons which are more echogenic and brighter than immature ones and appear as 'C-shaped'.

Because of the small number of suitable images, the 9 data of CRL recorded in the stage D61 to D77 were not considered in the statistical model. The result of the Mixed model procedure, analysing 207 CRL records, provided a statistically significant result for the effect of the pregnancy stage ( $p < 0.001$ ; Figure 3), but not significant for the effect of both the covariates. Indeed, p-values for parity and lambing rate were respectively at 0.316 and 0.342. Finally, 2.21% of the total variance was attributable to the random effect of the single sheep.

Results from the analysis carried out with Fisher's exact test on 256 records regarding ossification of the fetuses and placental cotyledons, measured by the respective visual scale score, are reported in Table 2.

Based on the aspect of both ossification and cotyledons, it was possible to differentiate stage D31-D35 from D36-D40, D36-D40 from D41-D45, and D41-D45 from D46-D50. The pregnancy stage D24-D30 was indistinguishable from D31-D35, and similarly D46-D50 from the successive ones, until D92.

Ultrasound images with different scores of foetal ossification and development of placental cotyledons stage during the pregnancy stages are reported in Figure 2.

## DISCUSSION

After D60 the achievement of CRL was ever more difficult, as also reported by Jones and Reed<sup>3</sup> (2017), and D77 was the last day a foetus was framed in a single image of the scanner's screen. Mean data are in agreement with those reported by Valasi et al.<sup>19</sup> for the sheep species.

The descriptive statistics of the 216 data regarding CRL (Table 1), even if achieved from a small number of sheep, could be the starting point for next studies related to the detection

of the probable stage of pregnancy and predict the lambing date referred to the Sarda sheep breed. The practical discussion of the results represented in Figure 3 indicates that it was always possible to discriminate the CRL of the fetuses of Sarda sheep throughout all the stages of pregnancy. In addition, the influence on CRL attributable to the parity, the lambing rate and the individual ewe were almost null. This last result allows to estimate the stage of the foetus regardless of the other phenotypic effects of the examined ewe, as the parity, multiple pregnancy and the individual animal. As regard the method in the case of ewes with multiple pregnancy, the choice to achieve measures and data from the first foetus, as representative of the other fetuses, could be debatable and a source of bias if during the pregnancy twins or triplets have different growth and development. Nevertheless, this is what can be experienced by a field-veterinarian using ultrasound equipment in routine examinations of large flocks and when a short time is available to achieve data and measures.

The visual assessment of ossification and cotyledons from our study are in line with Valasi et al.<sup>19</sup>, who reported an evident ossification of many districts by day 50 of pregnancy, and a definite identification of cotyledons after 37 days of pregnancy, when those are C-like shaped. The measurement of cotyledons' diameter has been proposed as an instrument to predict pregnancy stage in sheep<sup>19</sup> but other authors have demonstrated the inconsistency of results<sup>20</sup>. Nevertheless, we consider that the visual assessment of cotyledons using a scale score is more immediate and useful than the precise measurement of placental structures. This could be beneficial and convenient in the case of on-field examinations of flocks with a large number of animals.

The results obtained in this research can be considered, to our knowledge and the most common scientific databases and search engines, the first publication on foetal staging in the ear-

ly period of pregnancy in the Sarda sheep breed. In a previous study regarding the Sarda sheep, Ferrari et al.<sup>21</sup> have shown that, using an ultrasound device equipped with a linear probe and the transrectal examination, pregnancy can be diagnosed at the 16<sup>th</sup> day pregnancy, in 100% of the sheep at the 20<sup>th</sup> day, and that the measurement of the embryonic diameter can be acquired from the 21<sup>st</sup> day. Also, Aziz and Lazim<sup>22</sup> have reported that a 3.5 MHz convex probe via the transabdominal technique is useful to obtain a diagnosis of pregnancy in 100% of cases from the 40<sup>th</sup> day of pregnancy for the Awassi sheep. The same authors<sup>22</sup>, and Scott<sup>5</sup> with regard to meat-specialized sheep, have reported that early diagnosis is crucial for the correct management of the farm economy, since it allows the separation of pregnant and non-pregnant sheep, and related operations, such as the correct drying off of ewes<sup>9</sup> and dietary management of the groups<sup>23</sup>. In agreement with those reports and the findings of the present study, the foetal staging of Sarda sheep based on the ultrasonographic measurement of the foetus, the observation of its ossification and the cotyledons could allow to predict the date of lambing in the case that the time of mating has not been monitored and registered<sup>18,19</sup>.

## CONCLUSIONS

Lambing management is a critical moment to flock management, and farmers frequently request to veterinarians, especially those involved in diagnostic imaging in the reproductive field, a prediction of the date of lambing. Prediction of the pregnancy stage in the Sarda sheep could be achievable with a high level of reliability, regardless of the possible influence of the individual sheep, parity, and multiple pregnancy. Data of the present study are useful for veterinarians working in sheep farms rearing the Sarda, to provide a consistent prediction of the date of lambing.

## Acknowledgements

The authors thank the farmer for joining the study.

## Conflict of interest statement

The authors declare that there are no conflicts of interest. This article is inspired by the thesis of the first author, Giulia Fenu [Title of the thesis: Studio ultrasonografico dell'evoluzione morfometrica nella stadiazione fetale della pecora Sarda (in Italian language: Ultrasonographic survey of morphometric foetal stadiation in the Sarda sheep), Specialization School in Animal Health, farming and productions, Department of Veterinary Medicine, University of Sassari, Italy, June 2021]. The thesis is accessible as a hard copy at the library of the University of Sassari and as electronic file at the online library (<http://eprints.uniss.it>), and it has not been published elsewhere.

## References

1. Root C.R., Spaulding K.A. (1994). Diagnostic imaging in companion animal theriogenology. *Semin Vet Med Surg (Small Anim)*, 9: 7-27.
2. Haibel G.K. (1990). Use of ultrasonography in reproductive management of sheep and goat herds. *Vet Clin North Am Small - Food Anim Pract*, 6: 597-613.
3. Jones A.K., Reed S.A. (2017). Benefits of ultrasound scanning during gestation in the small ruminant. *Small Rumin Res*, 149: 163-171.
4. Stieger-Vanegas S.M., McKenzie E. (2021). Abdominal imaging in small ruminants: liver, spleen, gastrointestinal tract, and lymph nodes. *Vet Clin North Am Small - Food Anim Pract*, 37: 55-74.
5. Scott P.R. (2017). Use of ultrasonographic examination in sheep health management - A general appraisal. *Small Rumin Res*, 152: 2-9.
6. Scott P.R. (2012). Applications of diagnostic ultrasonography in small ruminant reproductive management. *Anim Reprod Sci*, 130: 184-186.
7. Van Der Merwe D.A., Brand T.S., Steyn S., Hoffman L.C. (2022). Using ultrasound to predict fat deposition in growing lambs of different South African sheep breed types. *Small Rumin Res*, 210: 106670.
8. Meinecke-Tillmann S. (2017). Basics of ultrasonographic examination in sheep. *Small Rumin Res* 152: 10-21.
9. Crilly J.P., Politis A.P., Hame, K. (2017). Use of ultrasonographic examination in sheep veterinary practice. *Small Rumin Res*, 152: 166-173.
10. Hedia M.G., El-Belely M.S. (2021). Testicular morphometric and echotextural parameters and their correlation with intratesticular blood flow in Ossimi ram lambs. *Large Anim Rev*, 27: 77-82.
11. Sale S., Spezzigu A., Bua, S. (2013). Gestione riproduttiva nell'allevamento ovino in Sardegna. (In Italian: Reproduction management of sheep farming in Sardinia). *Summa Animali da reddito* 1: 24-26.
12. Spezzigu A.; Sale S.; Bua S. (2013). Ultrasonografia e management aziendale nei piccoli ruminanti (In Italian: Ultrasonography and farm management in small ruminants). *Summa Animali da reddito* 1: 11-17.
13. Gootwine E. (2021). Management of dairy animals, sheep: reproductive management. In: *Encyclopedia of Dairy Sciences*, Eds. McSweeney P., McNamara J., 3rd ed., vol. 2, 46-52. Academic Press, San Diego, CA, USA.
14. Ramos M., Juarez M. (2011). Sheep milk. In: *Encyclopedia of Dairy Sciences*, Eds. Fuquay J.W., Fox P.F., McSweeney P., 2nd ed., vol. 1., 494-502, Academic Press, San Diego, CA, USA.
15. Carta A., Casu S.M., Salaris S. (2009). Invited review: Current state of genetic improvement in dairy sheep. *J Dairy Sci*, 92: 5814-5833.
16. DAD-IS (2022). Domestic Animal Diversity Information System maintained and developed by FAO, Rome, Italy. Available at <https://www.fao.org/dad-is> last access January 13 2022.
17. Skliarov P., Pérez C., Petrusa V., Fedorenko S., Bilyi D. (2021). Induction and synchronization of oestrus in sheep and goats. *J Cent Eur Agric* 22: 39-53.
18. Barbagianni M.S., Ioannidi K.I., Vasileiou N.G.C., Mavrogianni V.S., Orfanou D.C. (2017). Ultrasonographic examination of pregnant ewes: From early diagnosis of pregnancy to early prediction of dystocia. *Small Rumin Res*, 152: 41-55.
19. Valasi I., Barbagianni M.S., Ioannidi K.S., Vasileiou N.G.C., Fthenakis G.C., Pournlis A. (2017). Developmental anatomy of sheep embryos, as assessed by means of ultrasonographic evaluation. *Small Rumin Res* 152: 56-73.
20. Stankiewicz T., Błaszczycza B., Udała J., Chundekkad P. (2020). Morphometric measurements of the umbilical cord and placentomes and Doppler parameters of the umbilical artery through ultrasonographic analysis in pregnant sheep. *Small Rumin Res* 184: 106043.
21. Ferrari M.V., Catone G., Giardina P., Petralia P., Ferrari L.D.R. (2009). Transrectal ultrasonography for early pregnancy determination in Sarda breed lambs. *Arch Vet Sci* 14: 198-203.
22. Aziz D.M., Lazim E.H. (2012). Transabdominal ultrasonography in standing position for pregnancy diagnosis in Awassi ewes. *Small Rumin Res* 107: 131-135.
23. Vouraki S., Skourtis I., Psychos K., Jones W., Davis C., Johnson M., Riaguas Rupérez L., Theodoridis A., Arsenos G. (2020). A decision support system for economically sustainable sheep and goat farming. *Animals* 10: 2421.