


# Clinical follow-up in fattening bulls affected by Bovine Respiratory Disease (BRD) after pharmacological treatment with Tulathromycin and Ketoprofen: clinical score and ultrasonographic evaluations



ENRICO FIORE<sup>1</sup>, ANASTASIA LISUZZO<sup>1\*</sup>, ANDREA BELTRAME<sup>2</sup>,  
BARBARA CONTIERO<sup>1</sup>, ELIANA SCHIAVON<sup>3</sup>, ELISA MAZZOTTA<sup>1</sup>

<sup>1</sup> Department of Animal Medicine, Production and Health, University of Padua, Viale dell'Università 16, 35020 Legnaro, Italy

<sup>2</sup> Veterinarian free Practitioner

<sup>3</sup> Istituto Zooprofilattico Sperimentale delle Venezie (IZSve), Viale dell'Università 10, 35020 Legnaro, Italy

## SUMMARY

Bovine respiratory disease (BRD) is recognized as one of the most important disease in beef industry because it may negatively influence animal welfare and farm economy. An early diagnosis is necessary to improve prognosis and outcome, as well to provide for specific management treatment for the affected animals. The aim of this study is to assess the feasibility of the ultrasonographic technique as diagnostic method for BRD in fattening bulls after pharmacological treatment with tulathromycin and ketoprofen. Sixty Limousine fattening bulls of  $10.23 \pm 1.37$  months' age belonging to a single farm were enrolled in this study. Animals were divided into two groups according to ultrasonographic score (US score) of lungs: Group C or control group (US score < 3; 29 animals), and Group D or disease group (US score  $\geq$  3; 31 animals). Both groups received a clinical examination and a TUS (thoracic ultrasonography) at time 0 (T0; day of restocking) and time 7 (T7; +21 days). Furthermore, group D received additional clinical examinations and TUS at time 1 (T1; day of diagnosis and treatment), time 2 (T2; +1 day), time 3 (T3; +2 days), time 4 (T4; +3 days), time 5 (T5; +7 days), and time 6 (T6; +14 days). Statistical differences between groups were evaluated by parametric and not-parametric test. The lung lesions such as total areas of hepatization and fluid alveolograms were measured and analyzed with mixed regression models over time. The two groups showed a significant difference both in US score and clinical symptoms (respiratory score, nasal and ocular discharges and rectal temperature) when comparing T1 of group D with T0 of group C. Over the time, the treatment of group D was effective in reducing the US score and rectal temperature after 2 and 1 days, respectively, while ocular discharges was reduced after 2 days. The ultrasound evaluation of the general health status showed an improvement after 7 days from treatment. However, a reduction of total areas of hepatization and fluid alveolograms were evidenced in 3 days. In conclusion, the pulmonary ultrasound has been evidenced as a feasible and sensitive tool both for BRD early diagnosis and treatment effectiveness evaluation in fattening bulls.

## KEY WORDS

Ultrasonography; Lung's lesions; Bovine Respiratory Disease; Tulathromycin; Fattening bulls.

## INTRODUCTION

Bovine respiratory disease (BRD) is a syndrome involving infectious agents, host immune response and environmental factors. Stressors as transport or dietary changes may predispose animals to primary infection by viral or bacterial pathogens<sup>1,2</sup>. Among viral agents that mostly contribute to BRD there are Bovine Herpesvirus type 1 (BHV-1), Parainfluenza-3 virus (PI3), Bovine Viral Diarrhea Virus (BVDV), Bovine Adenovirus and Bovine Respiratory Syncytial Virus (BRSV); whereas among bacterial agents there are *Mannheimia haemolytica*, *Mycoplasma bovis*, *Pasteurella multocida*, and *Histophilus somni*<sup>3</sup>. Clinical observations of systemic and respiratory signs are often used for the diagnosis of BRD. However, the combination

of these parameters present a low sensitivity and specificity, near to 60%, with a consequent treatment of healthy subjects or missed detection of sick animals<sup>4,5</sup>. Actually, BRD may be present as subclinical form, with lung lesions and without clinical signs<sup>6</sup>. Furthermore, BRD is recognized as one of the most important disease in beef industry because it may negatively influences the growth, long-term productivity and increases the costs due to treatment, mortality, and decreased feed efficiency<sup>4,7,8</sup>. An early diagnosis is necessary to improve prognosis and outcome of BRD, such as to facilitate specific management and correct treatment of animals<sup>5,9</sup>.

Ultrasonography is a non-invasive, cost-effective, practical and rapid method (only 20-30 seconds/time procedure in optimal condition) to diagnose BRD in field<sup>9-11</sup>. In fact, bacterial and viral agents of BRD may result in non-aerated lung lobules that allow the ultrasound investigation by the replacement of reverberation artifacts to hypoechoic and anechoic structures<sup>12-14</sup>. Compared to diagnosis based on clinical ob-

Corresponding Author:

Anastasia Lisuzzo (anastasia.lisuzzo@phd.unipd.it).

servation, lung ultrasonography shows a greater sensitivity, between 80 to 94%, and specificity, between 94 to 100%, according to different conditions and techniques<sup>10</sup>. These findings are important to perform an early diagnosis in order to reduce animal suffering and to avoid unnecessary antimicrobial treatments to avoid the antimicrobial resistance<sup>15</sup>. The aim of this study is to assess the feasibility of the ultrasonographic technique as diagnostic method for BRD in fattening bulls after pharmacological treatment with tulathromycin and ketoprofen.

## MATERIAL AND METHODS

### Animals and clinical examination

This study was conducted in February 2021 in a single beef fattening herd (Isola della Scala, Verona, Italy). A single stock of sixty Limousine fattening bulls was enrolled in this study with an average age of  $10.23 \pm 1.37$  months. Animals came from France and were kept on outdoor dirt-floor pens. A total mixed ration (TMR) was provided once a day and water was ad libitum.

All animals were weighed and vaccinated against bovine Parainfluenza-3 Virus (PI3), Bovine Viral Diarrhea Virus (BVDV), Bovine Herpes Virus-1 (BHV-1) and Bovine Respiratory Syncytial Virus (BRSV) (Cattle Master 4; Zoetis Italia S.r.l., Rome, Italy); against *Clostridium Spp.* (Bravoxin 10; MSD Animal Health Italia S.r.l., Rome, Italy); and against *Pasteurella haemolytica* (Risposal Pasteurella; Zoetis Italia S.r.l., Rome, Italy) on the day of restocking. Furthermore, an antiparasitic treatment with moxidectin (Cydectin 0.5% Pour on; Zoetis Italia S.r.l., Rome, Italy) was performed on the same day. All animals were evaluated after 21 days, and an average daily gain (ADG) was calculated. A vaccination booster for PI3, BVDV, BHV-1, BRSV and *Clostridium Spp.* was performed on the same day. All animals were singularly conducted in a cattle crush (Taurus MC Deluxe Gate; Te Pari, Oamaru, New Zealand) where received a clinical examination by veterinarian of Veterinary Teaching Hospital - University of Padua. The respiratory score (R score)<sup>16</sup> based on cough, nasal and ocular discharges, and rectal temperature was conferred on a scale of 0 to 3 for each parameter. Animals were considered sick when the total score was greater or equal to 5, or if at least two parameters were reported over than 2. Due to the different cut-offs for identifying sick animals, percentage of diseased animals based on R score (DA%) were calculated.

### Thoracic Ultrasonography (TUS) evaluation

A thoracic area from 10<sup>th</sup> to 3<sup>rd</sup> intercostal space (ICS) was shaved before performing the thoracic ultrasonography (TUS) and ethyl alcohol (90%) was used as a transducing agent. TUS evaluation was performed with portable ultrasound scanner (MyLabOne™, Esaote S.p.a., Genova, Italy) equipped with a multi-frequency convex probe (SC3421, Esaote S.p.a., Genova, Italy; 2.5-6.6 MHz).

Six lung areas were investigated: between 10<sup>th</sup> and 7<sup>th</sup> ICS for the caudal lung; between 6<sup>th</sup> and 5<sup>th</sup> ICS for the middle lung; and between 4<sup>th</sup> and 3<sup>rd</sup> ICS for the cranial lung of both sides. The firsts two ICS were not evaluated due to the heavy forelimb muscles of post-weaned beef calves as described by Pravettoni et al. (2021). All scans were performed with constant ul-

trasound settings frequency of 4.3 MHz, 15 cm depth acoustics window, 100% gray scale gain, and time-gain compensation was in a neutral position.

The ultrasonographic score (US score) on a 6-point scale<sup>10</sup> was established during TUS. According to it, a score of 0 was equal to a normal aerated lung; 1 indicated diffuse comet-tail artifacts without consolidation; 2 indicated lobular consolidation; 3 indicated lobar consolidation; 4 lobar consolidations of two lobes; and 5 indicated lobar consolidation of three or more lobes. An US score greater or equal to 3 was consistent with bacterial bronchopneumonia.

Images were saved in a digital imaging and communications in medicine (DICOM) format and used for a post-sampling quantitative assessment (MyLabDesk™, Esaote S.p.a., Genova, Italy) of lungs' lesions. The lung lesions such as hepatizations and fluid alveolograms were measured in cm<sup>2</sup> for the six lung's areas. The total lung consolidation represents the sum the US score for each area.

### Experimental study design and laboratory analysis

Animals were divided into two groups according to ultrasonographic score: group C and group D. The group C or control group had an US score lesser than 3 and enrolled 29 fattening bulls. Group D or disease group had an US score greater or equal to 3 and enrolled 31 fattening bulls. These animals were considered affected by bovine respiratory disease (BRD)<sup>10</sup> and received a single subcutaneous (SC) injection of a long-acting macrolide and non-steroidal anti-inflammatory (FANS) at the day of diagnosis (tulathromycin and ketoprofen, 2,5 mg/kg + 3 mg/kg, Draxxin plus, Zoetis Italia S.r.l., Rome, Italy).

Nasal swabs were collected from group D animals before drug treatment (35 cm swab length, and agarized blister pack; Medical Wire & Equipment Co Ltd, Corsham, United Kingdom). The nasal swabs were gathered in a cold box at 4 °C and delivered refrigerated laboratory of Istituto Zooprofilattico Sperimentale delle Venezie (IZSVe; Legnaro, Padua, Italy) within 1 hour. The nasal swabs were analyzed for bacterial culture and Minimum Inhibitory Concentration (MIC) evaluation. Group C and group D received clinical examination and TUS at time 0 (T0; day of restocking) and time 7 (T7; after 21 days). Furthermore, group D received additional clinical examinations and TUS at time 1 (T1; day of diagnosis and treatment), time 2 (T2; after 1 day), time 3 (T3; after 2 days), time 4 (T4; after 3 days), time 5 (T5; after 7 days), and time 6 (T6; after 14 days). No one animal of group C showed clinical signs suggestive for BRD or presented an US score greater or equal to 3 during the study. Moreover, 15 of the 60 beef fattening bulls presented a TUS indicative for BRD at the day of restocking, despite it was not possible the T0 evaluations for these animals.

### Data elaboration

In order to perform the statistical analysis, data were converted to numeric scale. Specifically, nasal and ocular discharges relevance was pointed as follow: absent = 0; unilateral = 1; bilateral = 2; and abundant bilateral = 3. Whereas lung TUS evaluations outlined a lesion scores: absence of lesions = 0; comet tail = 1; hepatization = 2; fluid alveolograms = 3; comet tail and hepatization = 4; comet tail and fluid alveolograms = 5; hepatization and fluid alveolograms = 6; comet tail, hepatization and fluid alveolograms = 7. The global lesion score was obtained through the sum of lesion score of each area.

## Statistical analysis

Statistical analysis was performed using R software ver. 4.0.3<sup>17</sup> implemented with “rcmdr” package and with S.A.S system software (version 9.4; SAS Institute Inc., Cary, North Caroline, USA). In general, a *p*-value ≤ 0.05 was accepted as significant.

The data distribution was assessed by Shapiro-Wilk normality test before all statistical analysis.

Statistical differences between the two groups were evaluated according to data distribution: two unpaired sample Wilcoxon test for not normally distributed data (US score, R score, nasal and ocular discharges) and t-test for normally distributed data (rectal temperature). The DA% was evaluated with z-test for two samples, whereas ADG was evaluated with one-way ANOVA test. A linear mixed models (LMM) was used to analyze differences of weight. The model considered as fixed factors group, time, and their interaction. Animal was considered as random and repeated effect.

The follow-up of group D during time was performed with Kruskal-Wallis test for not normally distributed data (US score, R score, nasal and ocular discharges, global lesion score, lesion score, hepatization's areas and fluid alveolograms' areas). The DA% was evaluated with k proportions chi-squares test. An LMM was used for rectal temperature. The model included the fixed factor of time, whereas animals was considered as repeated and random effect. The same model implemented with rectal temperature as covariate was used to evaluate the total area of hepatization. Instead, the total area of fluid alveolograms was evaluated with a generalized linear mixed model zero-inflated (GLIMMIX) with Poisson distribution which considered the same factors as previous model.

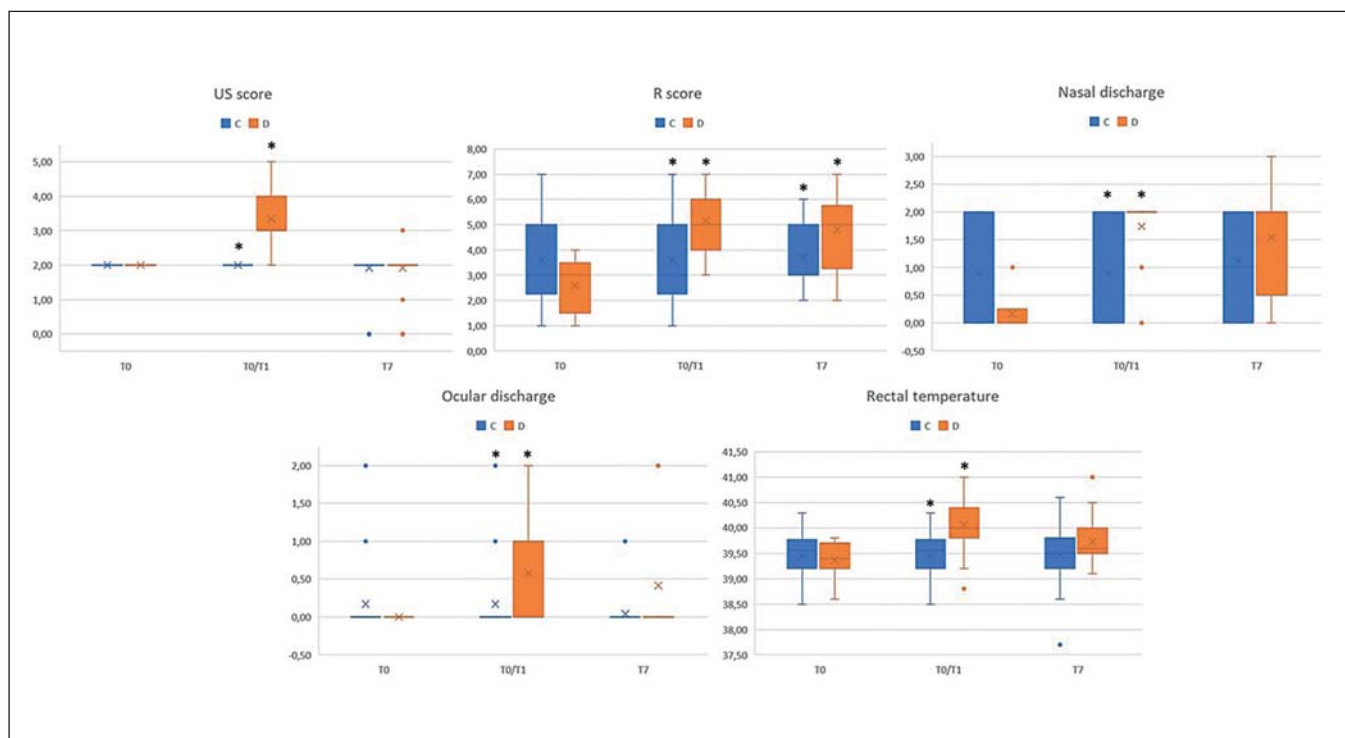
For all mixed models, post-hoc pairwise comparison among least squares means were performed using Bonferroni correction.

## RESULTS

The two groups did not show differences in weight at T0 and T7 (*p*-value = 0.398), and in ADG (1.72 kg/day in group C compared to 1.90 kg/day in group D; SEM = 0.15; *p*-value = 0.389). Furthermore, a significant time effect was evidenced (*p*-value < 0.0001) with a greater weight at T7 (407 kg for group C and 398 Kg for group D, SEM = 6.52) compared to T0 (371 kg for group C and 358 kg for group D, SEM = 6.42).

No significant difference in US score between groups at T0 (median value of 2 with interquartile range (IQR) of 2-2 in both groups in clinical findings were reported (Figure 1); *p*-value = 0.054). Whereas, comparing group D at T1 to group C at T0, a significant difference was evidenced (median value of 2 with IQR of 2-2 for group C and 3 with IQR of 3-4 for group D; *p*-value < 0.001). Alternatively, US score at T7 did not show difference between groups (median value of 2 with interquartile range (IQR) of 2-2 in both groups; *p*-value = 1.000).

R score did not report significant difference at T0 (*p*-value = 0.219), whereas a significant difference was showed between group D at T1 and group C at T0 (median value of 3 with IQR of 2.75-5 for group C and 5 with IQR of 4.5-6 for group D; *p*-value < 0.001), and between the two groups at T7 (median value 3 with IQR of 3-5 for group C and 5 with IQR of 3.75-5 for group D; *p*-value = 0.006). The DA% was significantly different between groups at T0 (42.86% for group C and 0% for group D; *p*-value = 0.036), between group D at T1 versus group C at T0 (42.86% for group C and 83.87% for group D; *p*-value = 0.001), and between groups at T7 (40.00% for group C and 75.00% for group D; *p*-value = 0.019). Cough was never observed in animals of both groups during the study. Nasal discharge was not significant at T0 (*p*-value = 0.105), while it was significantly different between group D at T1 and group C at



**Figure 1** - Box plot of clinical examination [ultrasonographic score (US score), respiratory score (R score), ocular and nasal discharges, and rectal temperature] of both groups (group D = orange, and group C = blue) at T0 and T7, and between T1 of group D and T0 of group C (T0/T1). Asterisk (\*) indicates significant differences between groups within parameter and time points.

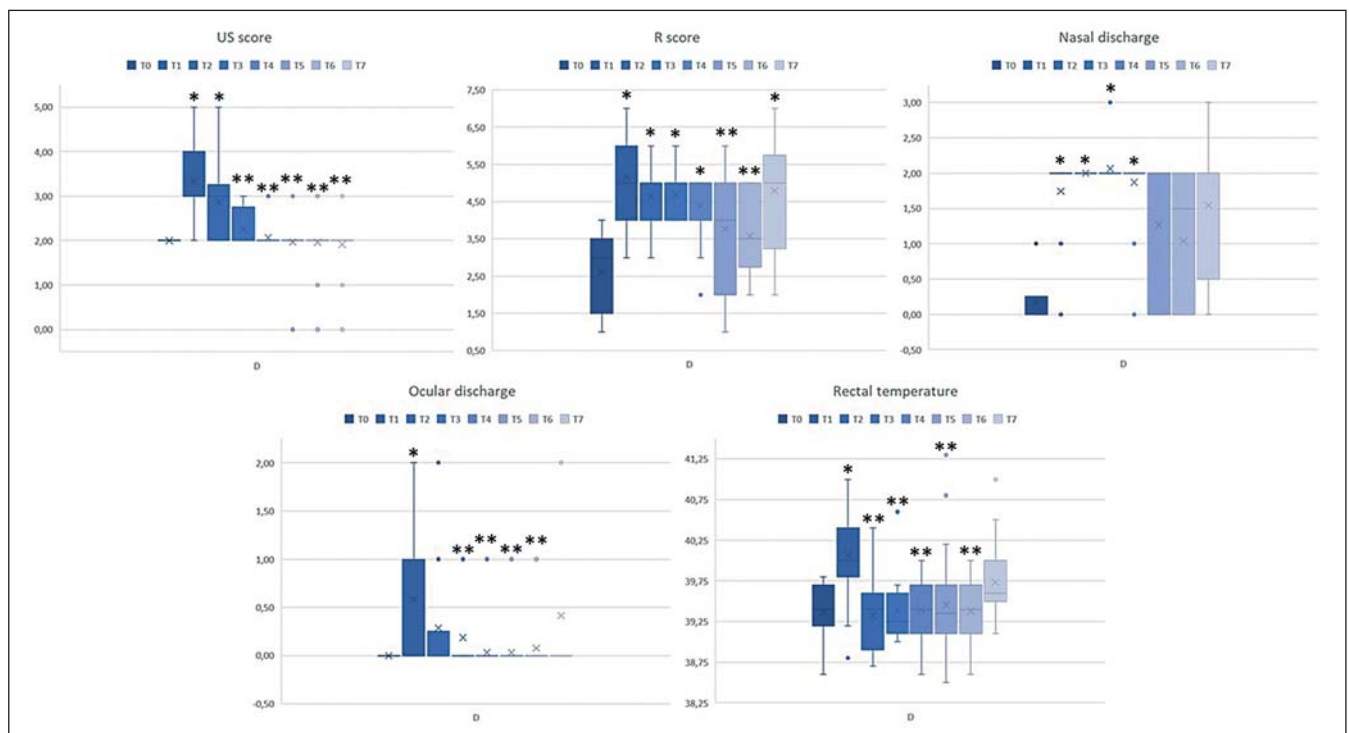
T0 (median value 0 with IQR of 0-2 for group C and 2 with IQR of 2-2 for group D;  $p$ -value < 0.001). However, this parameter was not significant at T7 ( $p$ -value = 0.097). Ocular discharge was not significant at T0 ( $p$ -value = 0.907), while it differed significantly between group D at T1 and group C at T0 (median value 0 with IQR of 0-0 for group C and 0 with IQR of 0-1 for group D;  $p$ -value = 0.039). However, a not significant difference was evidenced at T7 ( $p$ -value = 0.065).

Temperature assessment by rectal measurement was not significantly different between groups at T0 or T7 ( $p$ -value = 0.973 and 0.090, respectively), whereas a significant difference was present between group D at T1 and group C at T0 (39.45±0.46 °C in group C and 40.07±0.08 °C in group D;  $p$ -value < 0.001). In group D a significant difference was observed in all the examined clinical parameters over time (US score,  $p$ -value < 0.001; R score,  $p$ -value < 0.001; DA%,  $p$ -value < 0.001; nasal and ocular discharges,  $p$ -value < 0.001 and  $p$ -value = 0.003, respectively; and rectal temperature,  $p$ -value < 0.001; Figure 2).

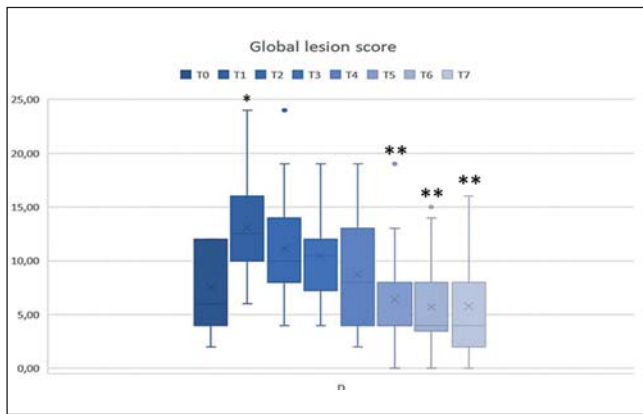
US score at T0 was significantly different from T1 (median value of 2 with IQR of 2-2 versus 3 with IQR of 3-4), whereas T1 varied significantly from T3 (median value of 2 with IQR of 2-2.25), T4, T5, T6, and T7 (median value of 2 with IQR of 2-2 for T4, T5, T6, and T7). R score at T0 was significantly different from T1 (median value of 3 with IQR of 2-3 versus 5 with IQR of 4.5-6), T2 (median value of 5 with IQR of 4-5), T3 (median value of 5 with IQR of 4-5), T4 (median value of 5 with IQR of 4-5), and T7 (median value of 5 with IQR of 3.75-5.25), whereas T1 differed from T5 (median value of 4 with IQR of 2.25-5) and T6 (median value of 3.5 with IQR of 3-5). DA% at T0 (0%) was significantly varied from all other time points (T1: 83.87%, T2: 92.86%, T3: 100%, T4: 87.10%, T5: 63.33%, T6: 46.15%, and T7: 75.00%), whereas no significant difference were evidenced between T1 and the other time points. Nasal

discharge at T0 were significantly different from T1, T2, T3, and T4 (median value of 0 with IQR of 0-0 at T0 versus 2 with IQR of 2-2 at T1, T2, T3, and T4), whereas T1 did not show a significant variation within the other time points. Ocular discharge at T0 differed significantly from T1 (median value of 0 with IQR of 0-0 versus 0 with IQR of 0-1), whereas T1 differed from T3, T4, T5, and T6 (median value of 0 with IQR of 0-0 for T3, T4, T5, and T6). Rectal temperature showed a significant changes between T0 and T1 (39.37±0.12 °C versus 40.07±0.08 °C), nevertheless T1 differed significantly from T2, T3, T4, T5, and T6.

The TUS evaluation in group D during clinical follow-up evidenced not significant changes about the lesion scores among the lung caudal areas ( $p$ -value = 0.165 and 0.622 for left and right caudal areas, respectively) and cranial lung areas ( $p$ -value = 0.073 and 0.454 for left and right cranial areas, respectively); conversely, significant variations in lesion scores among the lung middle areas ( $p$ -value < 0.001 and 0.001 for left and right middle areas, respectively) were reported. Particularly, TUS examination of the lung middle left area at T0 differed significantly from T1 (median value of 0 with IQR of 0-1 versus 3 with IQR of 0.75-6), whereas T1 varied significantly from T5, T6, and T7 (median value of 0 with IQR of 0-0 for T5 and T6, and IQR of 0-1 for T7). Furthermore, the TUS of the lung middle right area at T0 differed from T1 (middle value of 2 with IQR of 1-2 versus 2 with IQR of 0-4.5), while T1 differed significantly from T5, T6, and T7 (median value of 0 with IQR of 0-0.75 for T5, IQR of 0-0 for T6, and IQR of 0-0.5 for T7). The clinical follow-up showed a significant positive trend of the global lesion score ( $p$ -value < 0.001) (Figure 3), with a difference of T5, T6 and T7 (median value of 4 with IQR of 4-8 for T5 and T6, and IQR of 2-8 for T7) from T1 (median value of 12.5 with IQR of 10-16).



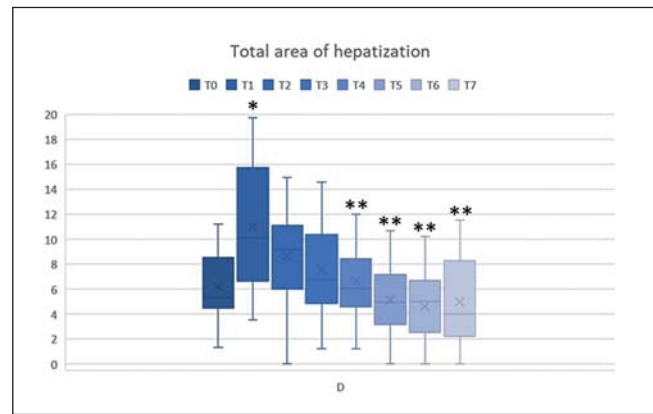
**Figure 2** - Box plot of clinical examination [ultrasonographic score (US score), respiratory score (R score), ocular and nasal discharges, and rectal temperature] of group D during clinical follow-up over time. One asterisk (\*) indicates significant differences of time points from T0 within parameter, while two asterisk (\*\*) indicates significant differences of time points from T1.



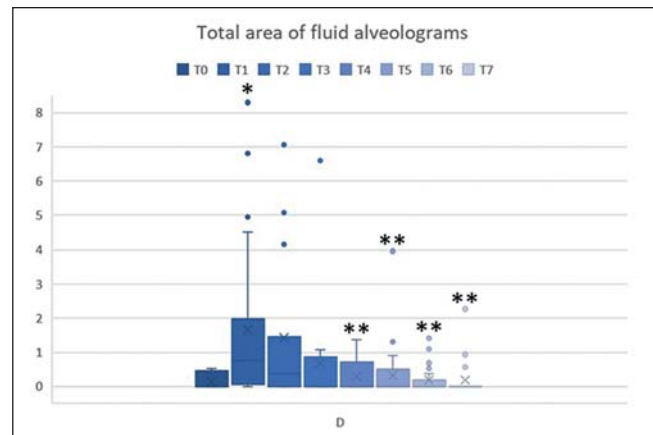
**Figure 3** - Box plot of global lesion score during clinical follow-up of group D over time. One asterisk (\*) indicates significant differences of time points from T0 within parameter, while two asterisk (\*\*) indicates significant differences of time points from T1.

In group D, the hepatization areas concerning both caudal lung regions did not present any significant trend over time ( $p$ -value = 0.213 and 0.622, respectively for left and right caudal lung); conversely, a significant positive trend for the middle lung ( $p$ -value < 0.001 and 0.001, respectively for left and right caudal lung). The evaluation of hepatized lungs areas of the cranial regions reported a significant difference in cranial right lung ( $p$ -value = 0.024) rather than cranial left lung ( $p$ -value = 0.086). Hepatization areas of the middle-left lung showed a significant reduction among T1, T5 and T6 (median value of 2 with IQR of 0-3.68 cm<sup>2</sup> versus 0 with IQR 0-0 cm<sup>2</sup> in T5 and T6), whereas the same parameter in right lung was sensibly reduced between T1 and T6 (median value of 1.64 with IQR of 0-4.79 cm<sup>2</sup> versus 0 with IQR 0-0 cm<sup>2</sup>). In addition, cranial right lung evaluation showed evidenced significant reduction between T1 and T5 (median value of 4.31 with IQR of 2.32-4.61 cm<sup>2</sup> versus 2.11 with IQR 1.30-3.09 cm<sup>2</sup>). Finally, total hepatization areas (Figure 4) reported a significant decrease between T1 (10.99±0.76 cm<sup>2</sup>) and T4, T5, T6 and T7 (6.72±0.65, 5.16±0.66, 4.64±0.70 and 5.02±0.75 cm<sup>2</sup>, respectively) ( $p$ -value < 0.001).

The fluid alveograms areas of both caudal lungs' regions ( $p$ -value = 0.500 and 0.525, respectively for left and right caudal lung) and cranial right lung ( $p$ -value = 0.267) were not significantly changed over time. Conversely, the middle lung areas reported significant variations ( $p$ -value < 0.001 and 0.001, respectively for left and right caudal lung), as though; the cranial left lung regions ( $p$ -value = 0.029). Fluid alveograms areas of the middle-left lung showed a difference between T0 and T1 (median value of 0 with IQR of 0-0 cm<sup>2</sup> versus 0 with IQR of 0-0.27 cm<sup>2</sup>) and between T1 and other time points (median value of 0 with IQR of 0-0 cm<sup>2</sup>); in right lung, this ultrasonographic parameter showed a similar trend in T1 (median value of 0 and IQR of 0-0.05 cm<sup>2</sup>). Cranial left lung areas reported differences among T0 and T1, and T2 (median value of 0 with IQR 0-0 cm<sup>2</sup> versus 0 with IQR 0-0.57 cm<sup>2</sup> for T1 and IQR of 0-0.64 cm<sup>2</sup> for T2), and between T1 and T3, T4, T5, T6 and T7 (median value of 0 with IQR 0-0.08 cm<sup>2</sup> for T3, IQR 0-0.10 cm<sup>2</sup> for T4, IQR 0-0 cm<sup>2</sup> for T5, T6 and T7). Furthermore, the total fluid alveograms areas presented significant differences among T1 (1.73±0.44 cm<sup>2</sup>) and T4, T5, T6, T7 (0.26±0.13, 0.31±0.14, 0.18±0.12, 0.21±0.14 cm<sup>2</sup>) ( $p$ -value = 0.004) (Figure 5).



**Figure 4** - Box plot of total area of hepatization in group D during clinical follow-up over time. One asterisk (\*) indicates significant differences of time points from T0 within parameter, while two asterisk (\*\*) indicates significant differences of time points from T1.



**Figure 5** - Box plot of total area of fluid alveograms in group D during clinical follow-up over time. One asterisk (\*) indicates significant differences of time points from T0 within parameter, while two asterisk (\*\*) indicates significant differences of time points from T1.

## DISCUSSION

Animal's transport for restocking represents an important stressor which may predispose beef cattle to infectious diseases. BRD is usually suspected when the animals show respiratory and ocular signs, besides the subclinical presentations are frequently not detected. Nevertheless, an early diagnosis is essential to avoid economic losses and preserve animal welfare<sup>8,18,19</sup>.

Animals affected by BRD often report lower ADG values compared to healthy<sup>10,20</sup>. The administration of tulathromycin have been reported to improve the ADG in BRD affected animals comparing to the control group<sup>21,22</sup>. This finding may be associate to a manipulation of ruminal fermentation that may positively influence animals' productivity<sup>3,23,24</sup>. Our results report no statistical differences between healthy and sick animals both in ADG or in body weight during the study period. These findings may suggest that an early treatment with tulathromycin could decrease the possibility of body weight reduction during the firsts 21 days of restocking.

R score showed greater value in group D at T1 compared to group C at T0, but no differences were evidenced between

groups at T0. The greater R score in group D at T1 may be attributed to higher incidence of nasal discharge, hyperthermia, and ocular discharges in this group. The evaluation of these parameters may be difficult because of the clinical presentation can be inconstant in terms of severity and persistency, particularly during the viral replication (hyperthermia followed by nasal and ocular discharges)<sup>2,6,25</sup>.

DA% showed greater value in group D at T1 compared to group C at T0, besides the control group reported a greater value compared to group D and C at T0. This finding may be associated to the detection of hyperthermia and the absence of cough. These parameters may be influenced by the stress for the animals during the operators handlings<sup>5,19</sup>. According to the literature, in our study 40% of sick animals were detected in group C (R score), confirming that clinical diagnosis may lack in specificity<sup>26</sup>.

Macrolides are often used to treat BRD due to their bacteriostatic capacity, accumulation on leucocytes and bronchial secretions, and for their greater concentration in lung tissue than plasma<sup>3,27</sup>. Particularly, tulathromycin has been reported effective both in targeting pathogens and in modulating the inflammatory response such as avoid uncontrolled self-perpetuating inflammation during BRD<sup>28</sup>. In addition, tulathromycin shows a higher clinical efficacy compared to other antimicrobial, as previously reported Nutsch et al. (2005) and Torres et al. (2013). Animals in group D showed significant greater US score, R score, DA%, nasal discharge and rectal temperature, whereas ocular discharge values at T1 (day of diagnosis and treatment) compared to T0 (day of restocking). These findings confirm the BRD typical presentation characterized by respiratory and systemic signs<sup>6</sup>. During the clinical follow-up after the treatment with tulathromycin and ketoprofen, the US score showed an improvement after 2 days (T3) and until the end of the study. The improvement of ultrasound lung scores may indicate the healing of the lung tissue<sup>30</sup>.

R score improved after 7 days (T5) and until 14 days (T6). However, among the parameters considered for R score, nasal discharge did not show a significant recovery, while ocular discharge and rectal temperature improved after 2 days (T3) and 1 day (T2), respectively, and until 14 days (T6). Nevertheless, DA% did not improve after the treatment.

Finally, US score, nasal and ocular discharges, or body temperature assessments reported no differences between group D and C at the end of the study period. Conversely, R score and DA% were statistically higher in group D.

TUS can be used to evaluate the severity of lung lesions represented as different degrees of non-aerated lung tissue (consolidation) due to inflammation and exudate deposits<sup>14,31</sup>. In group D, the global lesion score and the pulmonary middle areas score of both lungs showed a significant improvement after 7 days from treatment (T5) and until the end of the study. These findings suggest that general health status of lungs and single health status of middle areas improved after 7 days from treatment since the lesion score derives from the presence and the type of lesions on the investigated areas, while the global lesion score derives from the sum of the single lesion score.

The areas of hepatization and fluid alveolograms were evaluated to support the analysis of lung health status after treatment. In the present study, hepatization areas of middle left lung and cranial right lung improved after 7 days (T5), whereas they were improved after 14 days (T6) in the middle right lung. However,

the total hepatization areas showed a significant improvement after only 3 days from treatment (T4), with a reduction of about 6.00 cm<sup>2</sup> after 7 days (T5) and until the end of the study. However, some consolidated areas were still present after 21 days. The fluid alveolograms areas were improved after 1 day (T2), in the middle area of both lungs, and after 2 days (T3), in the cranial left lung until the end of the study. Moreover, the total area of fluid alveolograms improved after 3 days (T4) with a reduction of about 1.50 cm<sup>2</sup> after 7 days until the end of the study. According to the literature, the present study suggests that the combination of tulathromycin and ketoprofen can be successfully used in animals affected by BRD to treat acute lung lesions, particularly effective for the most sensitive pulmonic areas (cranial and middle lung of both sides)<sup>14,21,30</sup>. Moreover, the antimicrobics administration seems to be more efficient during early stage of the disease, in order to prevent the onset of chronic and severe pulmonary lesions.

## CONCLUSION

The use of pulmonary ultrasound was recognized to be a sensitive diagnostic method to assess respiratory diseases and the response to treatment in fattening bulls. Moreover, tulathromycin and ketoprofen treatment was effective in reducing the ultrasound score and rectal temperature after 2 and 1 days, respectively. Despite nasal discharge was not improved after the treatment, the ocular discharge was reduced after 2 days from the medical protocol. This study confirmed the cranial and middle areas of both lung sides are the most affected during BRD. The medical treatment has been reported efficient in reducing lung lesion after 3 days. Some areas of lung hepatization remained at the end of the study, confirming that the treatment is more effective in acute conditions of the disease.

**Acknowledgments:** The authors would like to thank the veterinarian Pietro di Salvo from Zoetis S.r.l. company and workers of the farm Cooperativa Agricola Zootechnica “La Torre” (Isola della Scala, Verona, Italy) for their help during the study.

**Author Contributors:** Conceptualization, E.F., A.L., and E.M.; Methodology, E.F., A.L., and E.M.; Software, B.C.; Formal analysis, A.L., B.C., and E.S.; Investigation, E.F., A.L., and A.B.; Resources, E.F., and E.S.; Data curation, E.F., and A.L.; Writing-original draft preparation, E.F., and A.L.; Writing-review and editing, E.F., A.L., E.M., and E.S.; Visualization, A.L.; Supervision, E.F.; Project administration, E.F.; Funding acquisition, E.F. All authors have read and agreed to the published version of the manuscript.

**Funding:** The study was supported by Zoetis S.r.l. regarding the costs of drug and ultrasound evaluations on the farm.

**Ethical approval:** No approval from Ethics Committee was required. No invasive medical procedures were executed to perform the study. The study was performed with the consent of the animals' owner during the routinary clinical activity of the Veterinary Teaching Hospital, University of Padua. Animal care and procedures are in accordance with the Guide for the Care and Use of Laboratory Animals and Directive 2010/63/EU for animal experiments (National law: D.L. 26/2014).

**Data Availability Statement:** The data will be available by sending an email to the corresponding author.

**Conflict of Interest:** The authors declare no conflict of interest.

## References

- McGill, J.L.; Sacco, R.E. The Immunology of Bovine Respiratory Disease. *Vet. Clin. North Am. - Food Anim. Pract.* 2020, 36, 333-348.
- Grissett, G.P.; White, B.J.; Larson, R.L. Structured Literature Review of Responses of Cattle to Viral and Bacterial Pathogens Causing Bovine Respiratory Disease Complex. *J. Vet. Intern. Med.* 2015, 29, 770-780, doi:10.1111/jvim.12597.
- Fiore, E.; Armato, L.; Morgante, M.; Muraro, M.; Boso, M.; Giancesella, M. Methaphylactic effect of tulathromycin treatment on rumen fluid parameters in feedlot beef cattle. *Can. J. Vet. Res.* 2016, 80, 60-65.
- Baruch, J.; Cernicchiaro, N.; Cull, C.A.; Lechtenberg, K.F.; Nickell, J.S.; Renter, D.G. Performance of multiple diagnostic methods in assessing the progression of bovine respiratory disease in calves challenged with infectious bovine rhinotracheitis virus and mannheimia haemolytica. *J. Anim. Sci.* 2019, 97, 2357-2367, doi:10.1093/jas/skz107.
- Abutarbush, S.M.; Pollock, C.M.; Wildman, B.K.; Perrett, T.; Schunicht, O.C.; Kent Fenton, R.; Hannon, S.J.; Vogstad, A.R.; Kee Jim, G.; Booker, C.W. Evaluation of the diagnostic and prognostic utility of ultrasonography at first diagnosis of presumptive bovine respiratory disease. *Can. J. Vet. Res.* 2012, 76, 23-32.
- Buczinski, S.; Fecteau, G.; Dubuc, J.; Francoz, D. Validation of a clinical scoring system for bovine respiratory disease complex diagnosis in preweaned dairy calves using a Bayesian framework. *Prev. Vet. Med.* 2018, 156, 102-112, doi:10.1016/j.prevetmed.2018.05.004.
- Holland, B.P.; Burciaga-Robles, L.O.; VanOverbeke, D.L.; Shook, J.N.; Step, D.L.; Richards, C.J.; Krehbiel, C.R. Effect of bovine respiratory disease during preconditioning on subsequent feedlot performance, carcass characteristics, and beef attributes. *J. Anim. Sci.* 2010, 88, 2486-2499, doi:10.2527/jas.2009-2428.
- Buczinski, S.; Borris, M.E.; Dubuc, J. Herd-level prevalence of the ultrasonographic lung lesions associated with bovine respiratory disease and related environmental risk factors. *J. Dairy Sci.* 2018, 101, 2423-2432, doi:10.3168/jds.2017-13459.
- Pravettoni, D.; Buczinski, S.; Sala, G.; Ferrulli, V.; Bianchi, F.; Boccardo, A. Short communication: Diagnostic accuracy of focused lung ultrasonography as a rapid method for the diagnosis of respiratory disease in dairy calves. *J. Dairy Sci.* 2021, 104, 4929-4935, doi:10.3168/jds.2020-19377.
- Ollivett, T.L.; Buczinski, S. On-Farm Use of Ultrasonography for Bovine Respiratory Disease. *Vet. Clin. North Am. - Food Anim. Pract.* 2016, 32, 19-35, doi:10.1016/j.cvfa.2015.09.001.
- Fabrizi, G.; Giancesella, M.; Morgante, M.; Armato, L.; Bonato, O.; Fiore, E. Ultrasonographic alterations of bovine claws sole soft tissues associated with claw horn disruption lesions, body condition score and locomotion score in Holstein dairy cows. *Res. Vet. Sci.* 2020, 131, 146-152, doi:10.1016/j.rvsc.2020.04.016.
- Flöck, M. Diagnostic ultrasonography in cattle with thoracic disease. *Vet. J.* 2004, 167, 272-280, doi:10.1016/S1090-0233(03)00110-2.
- Streeter, R.N.; Step, D.L. Diagnostic Ultrasonography in Ruminants. *Vet. Clin. North Am. - Food Anim. Pract.* 2007, 23, 541-574, doi:10.1016/j.cvfa.2007.07.008.
- Ollivett, T.L.; Caswell, J.L.; Nydam, D.V.; Duffield, T.; Leslie, K.E.; Hewson, J.; Kelton, D. Thoracic Ultrasonography and Bronchoalveolar Lavage Fluid Analysis in Holstein Calves with Subclinical Lung Lesions. *J. Vet. Intern. Med.* 2015, 29, 1728-1734, doi:10.1111/jvim.13605.
- Buczinski, S.; Pardon, B. Bovine Respiratory Disease Diagnosis: What Progress Has Been Made in Clinical Diagnosis? *Vet. Clin. North Am. - Food Anim. Pract.* 2020, 36, 399-423, doi:10.1016/j.cvfa.2020.03.004.
- McGuirk, S.M.; Peek, S.F. Timely diagnosis of dairy calf respiratory disease using a standardized scoring system. *Anim. Heal. Res. Rev.* 2014, 15, 145-147, doi:10.1017/S1466252314000267.
- Team R Development Core A Language and Environment for Statistical Computing. *R Found. Stat. Comput.* 2018, 2, https://www.R-project.org.
- Buckham Sporer, K.R.; Weber, P.S.D.; Burton, J.L.; Earley, B.; Crowe, M.A. Transportation of young beef bulls alters circulating physiological parameters that may be effective biomarkers of stress. *J. Anim. Sci.* 2008, 86, 1325-1334, doi:10.2527/jas.2007-0762.
- Timsit, E.; Dendukuri, N.; Schiller, I.; Buczinski, S. Diagnostic accuracy of clinical illness for bovine respiratory disease (BRD) diagnosis in beef cattle placed in feedlots: A systematic literature review and hierarchical Bayesian latent-class meta-analysis. *Prev. Vet. Med.* 2016, 135, 67-73, doi:10.1016/j.prevetmed.2016.11.006.
- Kiser, J.N.; Lawrence, T.E.; Neupane, M.; Seabury, C.M.; Taylor, J.F.; Womack, J.E.; Neiberghs, H.L. Rapid communication: Subclinical bovine respiratory disease - loci and pathogens associated with lung lesions in feedlot cattle. *J. Anim. Sci.* 2017, 95, 2726-2731, doi:10.2527/jas2017.1548.
- Godinho, K.S.; Wolf, R.M.L.G.; Sherington, J.; Rowan, T.G.; Sunderland, S.J.; Evans, N.A. Efficacy of tulathromycin in the treatment and prevention of natural outbreaks of bovine respiratory disease in European cattle. *Vet. Ther.* 2005, 6, 122-135.
- Nutsch, R.G.; Skogerboe, T.L.; Rooney, K.A.; Weigel, D.J.; Gajewski, K.; Lechtenberg, K.F. Comparative efficacy of tulathromycin, tilmicosin, and florfenicol in the treatment of bovine respiratory disease in stocker cattle. *Vet. Ther.* 2005, 6, 167-179.
- Armato, L.; Giancesella, M.; Fiore, E.; Arfuso, F.; Rizzo, M.; Zumbo, A.; Giudice, E.; Piccione, G.; Morgante, M. Effect of live yeast & yeast cell wall *Saccharomyces cerevisiae* diet supplementation on faeces chemical composition and growth performance in growing and finishing beef steers. *Large Anim. Rev.* 2016, 22, 203-210.
- Armato, L.; Giancesella, M.; Morgante, M.; Fiore, E.; Rizzo, M.; Giudice, E.; Piccione, G. Rumen volatile fatty acids × dietary supplementation with live yeast and yeast cell wall in feedlot beef cattle. *Acta Agric. Scand. A Anim. Sci.* 2016, 66, 119-124, doi:10.1080/09064702.2016.1272628.
- Blakebrough-Hall, C.; Dona, A.; D'occhio, M.J.; McMeniman, J.; González, L.A. Diagnosis of Bovine Respiratory Disease in feedlot cattle using blood 1H NMR metabolomics. *Sci. Rep.* 2020, 10, 1-12, doi:10.1038/s41598-019-56809-w.
- White, B.J.; Renter, D.G. Bayesian estimation of the performance of using clinical observations and harvest lung lesions for diagnosing bovine respiratory disease in post-weaned beef calves. *J. Vet. Diagnostic Investig.* 2009, 21, 446-453, doi:10.1177/104063870902100405.
- Mzyk, D.A.; Bublitz, C.M.; Martinez, M.N.; Davis, J.L.; Baynes, R.E.; Smith, G.W. Impact of bovine respiratory disease on the pharmacokinetics of danofloxacin and tulathromycin in different ages of calves. *PLoS One* 2019, 14, 1-23, doi:10.1371/journal.pone.0218864.
- Fischer, C.D.; Beatty, J.K.; Duquette, S.C.; Morck, D.W.; Lucas, M.J.; Buret, A.G. Direct and Indirect anti-inflammatory effects of tulathromycin in bovine macrophages: Inhibition of CXCL-8 secretion, induction of apoptosis, and promotion of efferocytosis. *Antimicrob. Agents Chemother.* 2013, 57, 1385-1393, doi:10.1128/AAC.01598-12.
- Torres, S.; Thomson, D.U.; Bello, N.M.; Nosky, B.J.; Reinhardt, C.D. Field study of the comparative efficacy of gamithromycin and tulathromycin for the treatment of undifferentiated bovine respiratory disease complex in beef feedlot calves. *Am. J. Vet. Res.* 2013, 74, 847-853, doi:10.2460/ajvr.74.6.847.
- Hussein, H.A.; Binici, C.; Staufenbiel, R. Comparative evaluation of ultrasonography with clinical respiratory score in diagnosis and prognosis of respiratory diseases in weaned dairy buffalo and cattle calves. *J. Anim. Sci. Technol.* 2018, 60, 1-11.
- Rademacher, R.D.; Buczinski, S.; Tripp, H.M.; Edmonds, M.D.; Johnson, E.G. Systematic thoracic ultrasonography in acute bovine respiratory disease of feedlot steers: impact of lung consolidation on diagnosis and prognosis in a case-control study. *Bov. Pract.* 2014, 48, 1-10.