


Management of post-urethral urinary obstruction due to struvite uroliths in a female buffalo calf (*Bubalus bubalis*)



KALLEMUCHIKAL MANIKANDAN MANJUSHA^{1#}, KHAN SHARUN^{1**}, ELANGO VAN KALAI SELVAN¹, ROHIT KUMAR¹, ABHISHEK CHANDRA SAXENA¹, PRAKASH KINJAVDEKAR¹, ABHIJIT MOTIRAM PAWDE¹, AMARPAL¹

¹Division of Surgery, ICAR-Indian Veterinary Research Institute, Izatnagar, Bareilly, Uttar Pradesh, India.

SUMMARY

Obstructive urolithiasis is an economically relevant disease of the ruminants. Male buffalo calves are most frequently affected compared to females because of their anatomical peculiarities. The occurrence of obstructive urolithiasis in females is a rare finding and requires documentation. A three-month-old female buffalo calf was presented with history of oliguria and stranguria in the past two days. General clinical examination identified that the animal was dull and restless with a rough hair coat, and congested mucus membrane. Abdominal palpation identified the presence of an enlarged urinary bladder. Based on history and clinical signs the condition was diagnosed as urinary tract obstruction. The hematological changes identified were neutrophilia and monocytosis and the serological parameters were within the normal range. Microscopic examination of the collected urine following sedimentation revealed the presence of numerous struvite calculi. It was decided to manage the case conservatively rather than going for invasive surgical procedure such as tube cystotomy. High resistance was encountered when a urinary catheter was passed through the urethra in the post-urethral region. The obstruction was relieved when the catheter was carefully maneuvered into the urethra. The animal was treated with parenteral antibiotics and oral ammonium chloride therapy following which the calf made an uneventful recovery.

KEY WORDS

Urinary obstruction; post-urethral; struvite calculi; buffalo; *bubalus bubalis*.

INTRODUCTION

Obstructive urolithiasis is a rare finding in female buffalo calves as compared to males. Anatomical peculiarities of the male urinary tract predispose them to calculi formation, especially in animals castrated before puberty. The health status and body condition of the animal solely depend on the duration of illness and the patency of urinary bladder¹. Diet is one of the major contributing factors in calculi development along with other physiological and management factors. Struvite is the major calculi detected in ruminants due to excessive feeding of concentrate as compared to roughage².

Diet rich in magnesium and phosphorus that is low in calcium and potassium predisposes to the formation of struvite calculi³. Occurrence of silica, oxalate, and carbonate calculi in urine are considered to be incidental findings in ruminants⁴. Tentative diagnosis of obstructive urolithiasis can be made from history, clinical signs, per rectal or abdominal palpation, urinalysis, radiography, ultrasonography and haemato-biochemical examination⁵.

In mild cases, the animals can be treated by using tranquilizers and antispasmodics⁶. Various treatment modalities, both medical and surgical have been developed in almost all the species for the management of urolithiasis^{7,8}. Despite sophis-

ticated surgical techniques and various supportive treatments prognosis of urolithiasis in bovine still remains unpredictable⁹. Medical management is optional depending on the condition of animal, clinical signs, severity, site of occurrence, number of calculi, and the economic status of the owner. Rupture of bladder may occur in delayed cases or due to administration of diuretics in ruminants². Time is an important factor that decides the prognosis of obstructive urolithiasis in ruminants.

The present paper describes about post urethral urinary obstruction in a female buffalo calf and its conservative management.

Case history and clinical findings

A 3-month-old female buffalo calf was presented to the surgery division of Referral Veterinary Polyclinic, IVRI, Bareilly, with the history of oliguria and stranguria in the past two days. On general clinical examination, the calf had a rough hair coat and turgid skin with sunken eyes. The calf exhibited frequent efforts to urinate and intermittent dribbling of urine was observed (Figure 1). The condition was diagnosed as obstructive urolithiasis based on the history and clinical signs. History indicated that the calf was exclusively fed on wheat bran diet as reported by the owner. Hematological parameters revealed marked neutrophilia and monocytosis. Biochemical analysis revealed marked increase in the serum creatinine and blood urea nitrogen (BUN) value indicating azotemia (Table 1).

Corresponding Author:

Khan Sharun (sharunkhansk@gmail.com / sharunkhan@ivri.res.in).

#Both K. M. Manjusha and Khan Sharun equally contributed to the work and therefore considered first authors.

Table 1 - Hematological and serological parameters of the buffalo calf with obstructive urolithiasis on the day of the presentation.

Hematological parameters			
Parameter	Day 0	Reference range ^a	Key findings
RBC count ($\times 10^6$ /L)	5.44	5.0-10.0	
PCV (%)	38.55	24-46	
Hemoglobin (g/dl)	12.6	8.0-15.0	
Total WBC count ($\times 10^3$ /L)	11.5	4.0-12.0	
Neutrophil (%)	48	15-33	Neutrophilia
Lymphocyte (%)	38	45-75	Lymphopenia
Monocyte (%)	14	0-8	Monocytosis
Eosinophil (%)	0	0-20	
Basophil (%)	0	0-2	
Platelets ($\times 10^3$ /L)	230	100-800	
Serological parameters			
Parameter	Day 0	Reference range ^a	Key findings
Total protein (g/dl)	6.54	6.7-7.5	
Albumin	3.1	2.5-3.8	
Globulin	3.44	3.0-3.5	
Total bilirubin (mg/dl)	0.2	0-1.6	
AST (IU/L)	73	60-125	
BUN (mg/dl)	48.2	10-25	Azotemia
Creatinine (mg/dl)	3.04	0.5-2.2	Azotemia

^aHematology and serum biochemical reference ranges, The Merck Veterinary Manual - 11th edition (2016)

DISCUSSION

Urinary calculi can occur anywhere in the urinary tract but it mostly depends upon the animal species. The occurrence of obstructive urolithiasis is rare in female calves compared to males. Knowledge on diet plays an important role in the predicting the nature of stone. A thorough investigation of the history should always precede the clinical examination. Young ruminants are mostly affected with this debilitating condition². The condition is caused by multiple etiologies including sex, age, type of feed, hormonal imbalances, season, reduced water intake, genetic makeup, early castration before sexual maturation, hypovitaminosis A, and the affections of bladder and urethra¹⁰. Tiruneh (2004) found that high level of oxalates and silica in



Figure 1 - Female buffalo calf presented with post-urethral urinary obstruction. The urine was constantly dribbling from the vulva (yellow arrow).

pasture plants were considered as major factors deciding the formation of uroliths in grazing animals¹¹. Moreover, provision of concentrate ration that is typically rich in phosphorus, or an imbalance in the calcium and phosphorus ratio, were stated as major causes of urolithiasis in feedlot animals. A calcium phosphorus imbalance in diet will precipitate the development of phosphate calculi due to high urinary excretion of

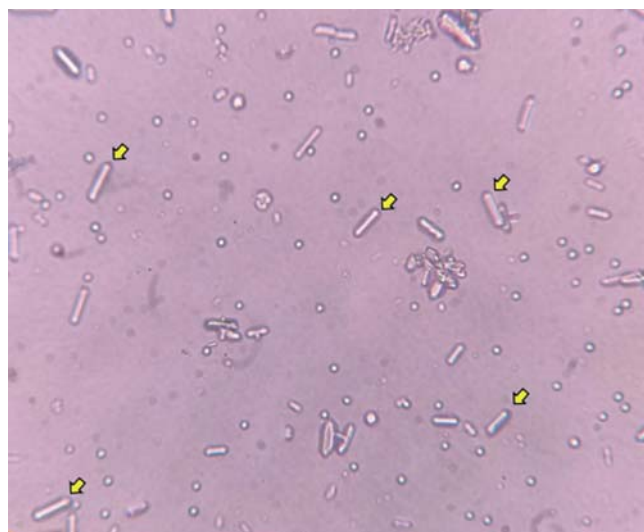


Figure 2 - Numerous calculi which are refractile and colorless along with erythrocytes and renal epithelial cells. The presence of 6 to 8 sided prisms and rectangles with coffin lid appearance is suggestive of struvite calculi (yellow arrow). In general, crystals can be orthorhombic, equant, wedge like, short prismatic, tabular, hemimorphic.

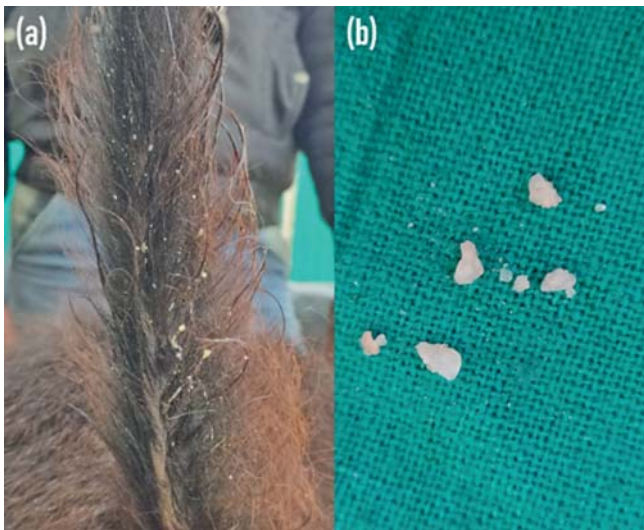

Figure 3 - (a) Multiple uroliths were found towards the base of the tail after relieving the obstruction. **(b)** Macroscopic struvite uroliths expelled through the urine.

phosphorus³. The shortage of drinking water could further act as a precipitating factor in the development of urolithiasis. Sharma et al. (2005) conducted study on twelve bovine calves suffering from urolithiasis. The haemato-biochemical parameters showed increased values of Hb, PCV, TLC, neutrophils, BUN, creatinine, inorganic phosphorus and potassium. According to the study, these parameters returned towards normal levels after surgical intervention and fluid therapy¹². Ruminants are the most susceptible group of animals that are affected by obstructive urolithiasis and is extensively reported in male sheep, goat and cattle⁴. Rupture of the bladder occur as a sequela to the complete obstruction of urethra due to lodgment of calculi¹³. Early signs of urethral obstruction include severe pain that leads to stranguria¹⁴. Sandy calculi which initially get lodged in the urethra may later lead result in complete urethral obstruction in young animals¹⁵. The treatment is based on history, clinical signs and the type of calculi with surgical correction being the supreme and ultimate choice.

CONCLUSION

Obstructive urolithiasis should be considered as an emergency condition in ruminants that requires immediate intervention. Stage of clinical presentation and condition of the animal is important in deciding the prognosis. Since the condition is having multifactorial etiology i.e. nutritional, physiological, and management factors, the treatment should be directed to resolve all these factors. Recurrence of calculi can occur either due to failure of treatment or due to lack of proper care. Furthermore, the formation of stones within the urinary tract is not a specific disease but is a potential complication of many different disorders. Therefore, a thorough knowledge about the pathogenesis of the condition is required for efficient and cost-management.

Acknowledgments

The authors are thankful to the Director, Indian Veterinary Research Institute, Izatnagar (UP) and Head, Surgery Division, Indian Veterinary Research Institute, Izatnagar (UP) for the facilities provided.

Funding

No substantial funding to be stated.

Disclosure statement

All authors declare that there exist no commercial or financial relationships that could, in any way, lead to a potential conflict of interest.

References

1. Kushwaha R.B., Amarpal K.P., Aithal H.P., Kinjavdekar P., Pawde, A.M. (2014). Clinical appraisal of 48 cases of obstructive urolithiasis in buffalo calves treated with tube cystostomy and urethrotomy. *Adv Anim Vet Sci*, 2(2): 106-110.
2. Amarpal K.P., Aithal H.P., Pawde A.M., Pratap K., Gugjoo, M.B. (2013). A retrospective study on the prevalence of obstructive urolithiasis in domestic animals during a period of 10 years. *Adv Anim Vet Sci*, 1(3): 88-92.
3. Radostitis O.M., Blood D.C., Gray G.C. Hinchcliff K.W. (2005). *Veterinary Medicine a text book of the disease of cattle, sheep, pig, goat and horse*. Bailliere Tindall, London, 1877.
4. Makhdoomi D.M., Ghazi M.A. (2013). Obstructive urolithiasis in ruminants- A review. *Vet World*, 6: 233-238.
5. Parrah J.D., Hussain S.S., Moulvi B.A., Makhdoomi D.M., Buchoo, B.A., Malik H.U. (2011). Ultrasonographic diagnosis of obstructive urolithiasis in calves. *Indian J Vet Surg*, 32(2): 117-20.
6. Elisa M., Ermilio M.C., Smith. (2011). Treatment of Emergency Conditions in Sheep and Goats. *Vet Clin North America: Food Anim Pract*, 27(1): 33-45.
7. Dubey A., Pratap K., Amarpal, Aithal H.P., Kinjavdekar P., Singh, T., Sharma M.C (2006). Tube Cystotomy and chemical dissolution of urethral calculi in goats. *Indian J Vet Surg*, 27(2): 98-103.
8. Janke J.J., Osterstock J.B., Washburn K.E., (2009). Use of Walpole's solution for treatment of goats with urolithiasis: 25 cases (2001-2006). *J Am Vet Med Assoc*, 234: 249-252.
9. Sharma A.K., Mohindroo J., Aithal H.P. (2009). Physiological, urological changes and surgical management of urethral obstruction in bovine 25 cases (2001-2006). *J Am Vet Med Assoc*, 234: 249-252.
10. Udall R.H. Chow F.H. (1969). The etiology and control of urolithiasis. *Adv Vet Sci Comp Med*, 13: 29-57.
11. Tiruneh R. (2004). Minerals and Oxalate content of feed and water in relation with ruminant urolithiasis in Adea district, central Ethiopia. *Revue De Med Vet*, 155(5): 272-77.
12. Sharma A.K., Mogha J.V., Singh G.R., Amarpal A., Aithal H.P. (2005). Clinico-physiological and haematobiochemical changes in urolithiasis and its management in bovine. *Indian J Anim Sci*, 75: 1131-1134.
13. Rajesh K., Sharun K., Naveen K.V., Sasikala R., Mohd A.B., Pawde A.M., Amarpal K. P. (2019). Management of obstructive urolithiasis in a bullock by urethrotomy. *J Pharmacognosy and Phytochemistry*, 8(3): 2080-2082.
14. Monaghan M.L., Boy, M.G. (1990). Ruminants Renal System: Diseases of the renal system. In: *Large Animal Internal Medicine*. C. V. S. Mosby Company, Philadelphia, 888-890.
15. Gugjoo M.B., Zama M.M.S., Amarpal K.P., Mohsina A., Saxena A. C., Sarode I.P. (2013). Obstructive urolithiasis in buffalo calves and goats: incidence and management. *J Adv Vet Res*, 3: 109-113.