

# A case of epiploic foramen entrapment of jejunal intestinal tract in an alpaca (*Vicugna pacos*) cria



LAKAMY SYLLA<sup>1</sup>, MARTINA CROCIATI<sup>1</sup>, DOMENICO CAIVANO<sup>1</sup>,  
VASILICA FLORY PETRESCU<sup>1</sup>, LORENZO PISELLO<sup>1</sup>, CALOGERO STELLETTA<sup>2</sup>

<sup>1</sup> Department of Veterinary Medicine, University of Perugia, Via San Costanzo 4, 06126 Perugia - Italy

<sup>2</sup> Department of Animal Medicine, Production and Health, University of Padova, Viale dell'Università 16, 35020 Legnaro (Padova) - Italy

## SUMMARY

Signs of colic in camelids are generally vague and non-specific. Diagnostic techniques are mainly based on physical examination; however, a transabdominal ultrasonography could be helpful to evidence the most common surgical lesions. An exploratory laparotomy or laparoscopy should be considered as an extension of the physical examination.

In the present case report, a 6 month old, 20 Kg bodyweight Alpaca cria with colic symptoms secondary to small intestine entrapment was referred to the Teaching Veterinary Hospital of University (OVUD) at the Department of Veterinary Medicine University of Perugia - Italy, and subjected to an exploratory laparotomy. The cria was firstly treated medically for anorexia and depression; but, upon deterioration of the health status, a laparotomy was performed, leading to the definitive diagnosis of the epiploic herniation of the jejunum tract.

On presentation at the OVUD, the patient appeared depressed, alternatively in sternal and lateral recumbency, with body temperature of 38.5°C, heart rate of 52 bpm; at auscultation of the abdomen the forestomach and intestinal motility were normal. Abdominal ultrasonography revealed that small intestines were dilated, with intraluminal fluid accumulation but normal motility.

Late morning of the third day, the clinical condition worsened and the patient presented sinus tachycardia (210 bpm), tachypnea (52) and dyspnoea. The Owner gave consent to proceed with an explorative laparotomy. At surgery there was no peritoneal fluid accumulation; all tracts of the gut were normal in term of colour and volume, except for a small area of jejunum which appeared dark reddish with fibrinous spots on its surface. The jejunum was hard in consistency at digital palpation and was entrapped in the epiploic foramen. Due to the necrotic lesions on the intestinal tract, the owner was informed and authorised the execution of the euthanasia.

At necropsy, topography of abdominal viscera was maintained, except for a 5 cm of small intestine that were entrapped within the epiploic foramen; it appeared with multifocal, brown-reddish, necrotic and haemorrhagic lesions.

Although herein the cria was positive to *E. macusaniensis* infection, there was any sign of diarrhoea in the previous weeks to hospitalization.

In conclusion, necropsy confirmed the diagnosis of small intestine herniation into the epiploic foramen with related severe acute necro-haemorrhagic enteritis.

## KEY WORDS

Alpaca cria; colic symptoms; intestinal entrapment; exploratory laparotomy.

## CASE HISTORY

Camelids are considered pseudo-ruminants as their gastrointestinal system is similar to but distinctly different from that of traditional four-chambered ruminants and have three anatomically and functionally distinct areas referred to as C1, C2, and C3; they rely on forestomach protozoal and bacterial fermentation to break down plant material to digest nutrients. Diseases of the gastrointestinal tract are considered to be the main causes of mortality in camelids; they include ulceration of C3, enteritis, intestinal wall perforation, intussusception, volvulus of the mesentery, meconium impaction, enteric impaction, ruptured gut, sep-

tic peritonitis, necrotizing enteritis and urinary bladder rupture<sup>1-7</sup>. Signs of colic in camelids are generally vague and non-specific, such as vocalizing, bruxism, getting up and lying down, refusing to stand, rolling, kicking or looking at the belly, peculiar stance, kyphosis, depression, pyrexia, anorexia, tachycardia, tachypnea, tenesmus, decreased fecal output, tense or painful abdomen, distended abdomen, polakiuria, C1 atony, and regurgitation<sup>2-4,6,8</sup>. Therefore, camelid patients should be strictly and frequently monitored when abdominal condition is suspected, in order to ensure a detailed observation of the several clinical features<sup>5</sup>.

In case of small intestinal obstruction even more violent clinical signs, such as rolling and thrashing, could be seen while the severity of clinical signs associated with lesions affecting the large intestine tend to be more subtle<sup>2</sup>. Diagnostic techniques are mainly based on physical examination; a transabdominal ultrasonography could be helpful to evi-

Corresponding Author:  
Lakamy Sylla (lakamy.sylla@unipg.it).



**Figure 1** - Two crias of the same age, approximately six months, at presentation at the OVUD. The male sick cria (on the right) was under-grown compared to the healthy female of the same age. Pain-related behavior, such as frequent recumbence and stand-up together with depression and anorexia, were shown.

dence the most common surgical lesions<sup>2</sup>. An exploratory laparotomy or laparoscopy should be considered an extension of the physical examination. The outcome of gastrointestinal surgery is often reliant upon early diagnosis and timely surgical intervention.

This case report described the clinical findings and surgical approach of intestinal tract herniation in the epiploic foramen in an alpaca cria.

A 6-month-old, 20 Kg bodyweight, intact male alpaca was referred to the Teaching Veterinary Hospital of University (OVUD) at the Department of Veterinary Medicine University of Perugia - Italy, with a history of poor somatic growth compared to other crias of the same age, progressive weight loss, lethargy, dehydration and colic symptoms.

On presentation at the OVUD, the patient appeared depressed, alternatively in sternal and lateral recumbency, with body temperature of 38.5°C, heart rate of 52 bpm; at auscultation of the abdomen the forestomach and intestinal motility were normal, oral and conjunctival mucous membranes were pinkish, apparent lymph nodes were normal and a monolateral epiphora from the right eye was noted (Figure 1).

The patient was immediately subjected to medical treatment including intravenous fluid therapy (750 ml Ringer Lactate, 250 ml of 5% Dextrose solution, 2 ml Desadrexon and 5 ml Dobetin, intravenously, at a rate of 45 ml/Kg over one hour). Abdominal ultrasonography was performed using an ultrasound machine equipped with a 3-8 MHz convex transducer (MyLab 30 Gold, Esaote, Genova, Italy) after clipping the fiber of interested areas. The cria was examined in lateral recumbence in order to check the gastrointestinal tract. Small intestine was dilated, with intraluminal fluid accumulation and normal motility. The urinary bladder was normal in appearance and fluid-filled; both kidneys presented normal echostructure. No peritoneal effusion was present, while other abdominal organs were unremarkable.

At presentation the glycaemia was 320 mg/dl; therefore, the cria was subjected to an IM injection of 40 UI of human insulin. One hour later the glycaemia decreased to 269 mg/dl. The following morning, blood analysis was carried out; the

glycaemia decreased to 48 mg/dl, requiring a fast intravenous administration of a 33% dextrose solution diluted in 100 ml of saline solution over 15 min (Tables 1 and 2). General body condition was stationary and normal, except that the patient was still anorexic.

At day 1 post-recovery, the cria was subjected to an ophthalmological examination that evidenced a right corneal ulcer; a local therapy was instituted by application of Colbiocin® TID. Gastric antiulcer and anti-inflammatory treatments were started with Sucralfate® at the dose of 25 mg/kg per OS four times a day and Flunixin Meglumine 0.5 mg/kg IV once a day, respectively.

During the previous days, the cria continued to evacuate normal faeces, even if in small amount.

**Table 1** - Blood cells count of the cria at day one of presentation at the OVUD.

	Value	Reference limits <sup>7,9</sup>
RBC (x106/ $\mu$ L)	10.15	9.1 - 13.8
Hb (g/dL)	11.3	10.4 - 17.0
Htc (%)	20.1	24 - 36
MCV (fL)	19.8	21.8 - 28.9
MCH (pg)	11.1	10.6 - 12.7
MCHC (%)	56.2	39.3 - 46.8
WBC (x103/ $\mu$ L)	6.98	5.7 - 32.9
Neutrophils (%)	84.1	49 - 65
Lymphocytes (%)	14.8	21 - 25
Monocytes (%)	1.1	0 - 5
Eosinophils (%)	0.0	6 - 22
Basophils (%)	0.0	0 - 0.5
PLT (x103/ L)	323	200 - 600

**Table 2** - Biochemistry profile of the cria at day one of presentation at the OVUD.

	Value	Reference limits <sup>7,9</sup>
AST (IU/L)	230.0	137.0 - 391.0
ALP (IU/L)	466.0	32.0 - 167.0
GGT (IU/L)	12.0	13.0 - 50.0
Cholesterol (mg/dL)	31.0	15.5 - 88.9
Triglycerides (mg/dL)	5.0	10.62 - 45.14
BUN (mg/dL)	48.0	21.62 - 60.66
CPK (IU/L)	208.0	56.0 - 662.0
LDH (IU/L)	951.0	10.0 - 695.0
Creatinine (mg/dL)	1.56	1.0 - 2.4
Glucose (mg/dL)	48.0	90.0 - 149.0
Calcium (mg/dL)	9.1	4.2 - 9.0
Sodium (mEq/L)	152.0	144.0 - 155.0
Potassium (mEq/L)	2.1	4.0 - 5.7
Chloride (mEq/L)	117.0	97.0 - 111.0
Total proteins (g/dL)	5.3	5.7 - 7.2
Albumin (g/dL)	3.99	2.9 - 4.3

Late morning of the third day, the clinical condition worsened and the patient presented sinus tachycardia (210 bpm), tachypnea (52) and dyspnoea (open mouth breathing). An additional abdominal ultrasound was performed, confirming the excessive fluid content in small intestine with normal peristalsis. Forestomachal compartments appeared dilated. A gastric tubing was performed in order to empty the C1 compartment; few hours later he started to evacuate a discrete amount of catarrhal faeces. The farmer was informed about the deterioration of the clinical condition and was requested for the authorization to proceed with an explorative laparotomy, due to the suspicion of an obstructive ileus.

General anaesthesia was obtained with a mixture of Xylazine (0.46 mg/kg), Ketamine (4.6 mg/kg) and Butorphanol (0.046 mg/kg) administered intramuscularly. Then, anaesthesia was maintained with Isoflurane (MAC 1.1) and Oxygen through a tracheal intubation (size 8.5 length 13 cm). Surgical preparation and scrub of the ventro-caudal region was achieved and routine laparotomy procedure was performed between the navel scar and the prepubic tendon attachment. There was no peritoneal fluid accumulation; forestomachal compartments were all excessively dilated with fluid content. Therefore, two different sites gastrotomy were performed on both C1 and C3 in order to evacuate abnormal liquid content mixed to ingesta. More in detail, gastrotomy site in C1 was identified in the dorsal aspect of the caudal sac, 2 cm above and in right-direction from the glandular sacculles of the first compartment. The incision of C3 was performed on the ventral aspect of the terminal part, corresponding to the curvature before pyloric area. Almost all tracts of the gut were normal in term of colour and volume, except for a small area of jejunum which appeared dark reddish with fibrinous spots on its surface. The jejunum was hard in consistency at digital palpation and was entrapped in the epiploic foramen (Figure 2).

The intestinal tract was freed by small incision in the ring of the epiploon combined by gentle traction. Due to the necrotic lesions on the intestinal tract, the owner was informed and authorised the execution of the euthanasia. This intestinal tract has been later recognized as herniated and entrapped in epiploic foramen. Due to proximity to pylorus, presence of fibrin, and to involvement of pancreatic mesenteric area, the cria was euthanized.

At necropsy, body condition score was 2/5, mucous membranes appeared normal; a focal ulceration was present in the right conjunctiva. A moderate sero-haemorrhagic fluid peritoneal accumulation was observed in the abdominal cavity. Topography of abdominal viscera was maintained, except for a 5 cm of small intestine that were entrapped within the epiploic foramen; it showed multifocal, brown-reddish, necrotic and haemorrhagic lesions (Figure 3).

Its content included fluid and semisolid material and brown-reddish in colour; the wall showed the typical aspect of necro-haemorrhagic enteritis. The C1 forestomach presented a fresh surgical suture line; moderate amount of ingesta was present in the digestive tract and the mucosa of C3 showed a segmental hyperaemia, corresponding to the second gastrotomy site. Mucosa of the ileus showed sub-mucosal haemorrhages which were compatible with haemomelasma ilei. Kidneys, spleen and liver gross anatomy appeared normal in position and morphology. Light sero-haemor-

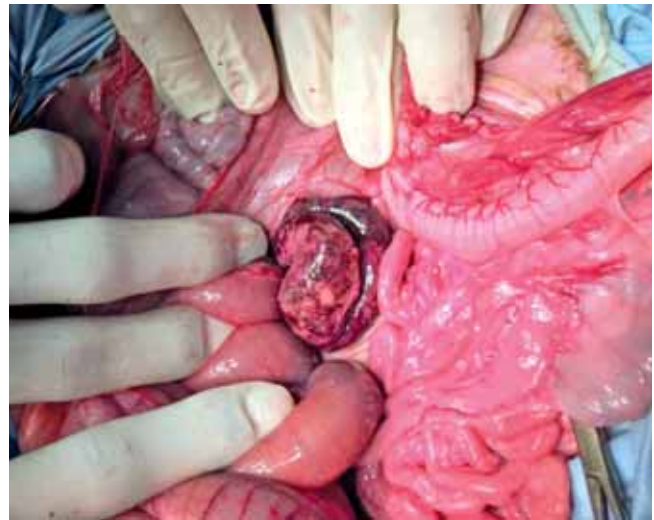


Figure 2 - Intraoperative view of necrotic small intestinal loop found during explorative laparotomy of the male cria.

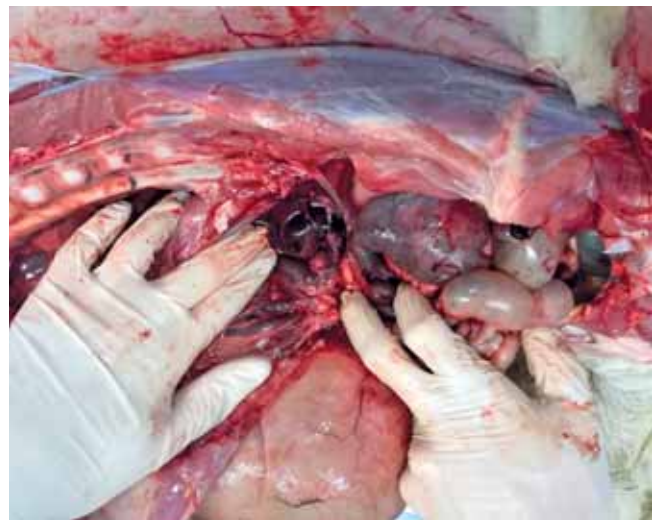

Figure 3 - Necropsy findings in the abdominal cavity of the six-months old cria. The topography of the gastrointestinal tract was conserved, except for a small intestinal loop, 5 cm long, which resulted entrapped within the epiploic foramen. The wall of the herniated organ was hemorrhagic and necrotic. In the picture, forestomach were moved ventrally to allow visualization of the herniation area.

rhagic fluid accumulation was found in the thoracic cavity and post mortem congestion stasis was present in the right lung. Heart was normal in dimension and morphology.

Small intestinal tract histopathology showed severe necrosis in the sub-mucosa and *lamina propria* haemorrhages and occasionally in the muscular layers. Diffuse lymphocyte infiltration (Mucosa-Associated Lymphoid Tissue or MALT hyperplasia) was found associated to blood vessel congestion. In forestomach sections, slight MALT hyperplasia was evident; occasionally, necrosis and bacterial overgrowth were identified, probably due to post-mortem alteration. Lung sections revealed congestion and edema into the alveoli. Spleen sections showed moderate but diffuse bloody congestion, while kidneys were normal in appearance.

In the present case report, a 6 month old Alpaca cria with colic symptoms secondary to jejune entrapment was subjected to an explorative laparotomy. The cria was firstly treated medically for anorexia and depression; but, upon deteriora-



tion of the health status, a laparotomy was performed, leading to the definitive diagnosis of the epiploic herniation of the jejune tract.

Secondary intestinal entrapments are more common in camelids that had previous abdominal surgery or infection; however, in the present case there was no history of previous abdominal surgery<sup>2,3,5,6</sup>. Intestinal entrapments generally involve the caudal flange of the jejunum, ileum, cecum, or ascending colon; these intestinal tracts may migrate through the epiploic foramen (as in the present study) or a defect in the body wall or diaphragm<sup>2,3,6</sup>. Risk factors for entrapments are very different from those for intraluminal obstructions such as congenital, acquired, or iatrogenic defects of the mesentery or walls of the peritoneal cavity.

Camelids with intestinal entrapments may continue to evacuate small quantities of normal or blood-tinged faeces whereas consistent passage of small amounts of diarrhoea in spite of on-going pain signs for up to 4 days is common with infection by *Eimeria macusaniensis*. Although herein the cria was positive to *E. macusaniensis* infection, there was no sign of diarrhoea before hospitalization.

Thorough examination and use of appropriate diagnostics including blood and biochemistry profiles, abdominocentesis and ultrasonography should help in reaching a diagnosis. Exploratory surgery is warranted for crias showing severe abdominal pain and gross distension of intestinal loops, particularly if no faecal material is being passed or if the crias fail to improve on medical therapy.

In conclusion, necropsy confirmed the diagnosis of small intestine herniation into the epiploic foramen with related severe acute necro-haemorrhagic enteritis.

## ACKNOWLEDGMENTS

No third-party funding or support was received in connection with this study or the writing or publication of the manuscript.

## CONFLICT OF INTEREST

The authors declare that there were no conflicts of interest.

## References

1. Kennel AJ. Health of farmed llamas and alpacas in North America. Results of a survey of llama veterinary practitioners. *Int Llama Assoc* 1992; pag 1-3.
2. Cebra CK, Cebra ML, Garry FB, Larsen RS, Baxter GM. Acute gastrointestinal disease in 27 New World camelids: clinical and surgical findings. *Vet Surg* 1998; 27:112-21.
3. St-Jean G, Anderson DE, Anderson NV, Hoskinson J. Abdominal pain associated with an umbilical abscess in a llama. *Cornell Vet* 1993; 83:77-81.
4. Costarella CE, Anderson DE. Ileocecolic intussusception in a one-month-old llama. *J Am Vet Med Assoc* 1999; 214:16C72-3, 1640.
5. Bickers RJ, Templer A, Cebra CK, Kaneps AJ. Diagnosis and treatment of torsion of the spiral colon in an alpaca. *J Am Vet Med Assoc* 2000; 216:380-2.
6. Black-Schultz LL, Hanson PD, Wilson DG, Markel MD. Diaphragmatic hernia in a llama. *J Am Vet Med Assoc* 1993; 1993:410-2.
7. Vencato J, Fiore E, Morgante M, Stelletta C. Gastric ulcers in south american camelids. *Large Animal Review* 2012; 18:123-127.
8. Smith JJ, Dallap BL. Splenic torsion in an alpaca. *Vet Surg* 2005; 34:1-4.
9. Foster A, Bidewell C, Barnett J, Sayers R. Haematology and biochemistry in alpacas and llamas. *In practice* 2009; 31:276-281.